



Bracing for scoliosis in 2014: state of the art

F. ZAINA¹, J. C. DE MAUROY¹, T. GRIVAS³, M. T. HRESKO⁴, T. KOTWIZKI⁵, T. MARUYAMA⁶
N. PRICE⁷, M. RIGO⁸, L. STIKELEATHER⁹, J. WYNNE¹⁰, S. NEGRINI¹¹

Bracing is currently the primary method for treating moderate idiopathic scoliosis (IS) during the developmental phase of growth. Following a lengthy debate, during which researchers and authors questioned the role of bracing in the treatment of IS due to inconsistent evidence, the Bracing in Adolescent Idiopathic Scoliosis Trial study have provided a high level of evidence to the value of bracing and may have convinced most of those who were skeptic. However, although some guidelines have been published, there remains no standard for constructing scoliosis orthoses and no standard treatment protocol. The Scoliosis Research Society criteria were established to provide a framework by which to research bracing and adolescent idiopathic scoliosis, and the Society on Scoliosis Orthopedic and Rehabilitation Treatment criteria were published to guarantee a minimum level of expertise for MDs and CPOs involved in the brace treatment. However, very few contemporary papers follow both sets of criteria, and the extensive variety of braces makes it difficult to determine if one is superior to another. The aim of this paper is to provide an overview of state-of-the-art brace treatment, highlighting commonly used braces and their history, biomechanical concept, and results, as reported in published literature. Specific focus is placed on European (*i.e.*, Chêneau and derivatives, Dynamic Derotating, Lyon, PASB, Sforzesco, TLI, TriaC) and North American (*i.e.* Boston, Charleston, Milwaukee, Providence, Rosenberger, SpineCor, Wilmington) designs. Details about different building techniques are also reported, along with recently developed tools that are designed to monitor compliance.

KEY WORDS: Scoliosis - Braces - Adolescents.

Corresponding author: F. Zaina, ISICO (Italian Scientific Spine Institute), via Bellarmino 13/1, 20141 Milan, Italy.
E-mail: fabio.zaina@isico.it

¹ISICO (Italian Scientific Spine Institute), Milan, Italy

²Clinique du Parc, Lyon, France

³"Tzanio" General Hospital of Piraeus, Athens, Greece

⁴Children's Hospital Boston

Harvard Medical School, Boston, MA, USA

⁵Poznan University of Medical Sciences, Poznan, Poland

⁶Tokyo University, Tokyo, Japan

⁷University of Missouri, Kansas City, USA

⁸Istituto Elena Salvà, Barcellona, Spain

⁹Scoliosis Solutions, LLC, Fairfax, VA, USA

¹⁰Boston Brace, Boston, MA, USA

¹¹University of Brescia, Brescia

IRCCS Don Gnocchi, Milan, Italy

Currently, the leading treatment for moderately severe idiopathic scoliosis (IS) during the developmental phase is bracing.¹ Following a lengthy debate, during which researchers and authors questioned the role of bracing in the treatment of IS due to inconsistent evidence, the Bracing in Adolescent Idiopathic Scoliosis Trial (BrAIST) study has provide high level evidence to the value of bracing to reduce the likelihood of progression to surgical treatment and may have convinced most of those who were skeptic.² The Cochrane review (performed prior to Weinstein publication on BrAIST) reported low-quality evidence in favor of bracing for IS;^{3, 4} however, due to the lack of randomized control trials (RCTs), after the failure of a Dutch RCT due to the impossibility of recruiting patients, there has been a further attempt to carry out a randomized clinical study.^{5, 6} Unfortunately, this study failed in randomizing patients due to their willingness to decide which treatment

to undergo, and turned to a prospective observational study.² This BrAIST study favored bracing to reduce the rate of surgery in AIS cases, with consistent results in both arms: both randomized and observed. In addition, a linear relationship of brace compliance (hours of brace wear) and success of treatment was found.

Among the limits to creating strong literature regarding bracing, a standard to building spinal orthosis⁷ and standard treatment protocols exists.⁸ The Scoliosis Research Society (SRS) established criteria to allow for improved AIS research,⁹ and the SOSORT published criteria to guarantee a minimum level of expertise for MDs and CPOs involved in the orthotic treatment of IS.¹⁰ Nevertheless, only a few IS research projects follow these criteria.

The aim of this paper was to summarize the state-of-the-art brace treatment, reflecting different international brace types, focusing on European and North American designs. Different building techniques are also detailed, along with tools designed to monitor compliance. As inclusion criteria, we

considered only the most used braced with some scientific evidence of results possibly out of brace but at least in brace.

European Scoliosis braces

All braces reported in this paper are summarized in Table I, where data are resumed according to the Brace-Map classification system.¹¹

Chêneau brace

The Chêneau brace, initially called the Cheneau-Toulouse-Munster brace (CTM), was developed in the 1960s.¹² Currently accepted and used worldwide, this rigid brace provides 3-dimensional correction and opens anteriorly.¹³

The Chêneau brace is divided into zones and provides large, free spaces opposite pressure sites. The hump presses on 1/3 of the surface of the apex, and

TABLE I.—Summary of the all braces reported in this paper. NA=not applicable; full time: more than 18-20 hours a day; part time: 10 to 18; night time: less than 10, only during sleeping.

Brace	Origin	Developer	Building	Construction	Rigidity	Material
Classification			B		R	
Boston	USA	J Hall, W Miller	P: prefabricated envelope	Prefabricated models	R: Rigid	polyethylene
Charleston	USA	F Reed, R Hooper			R: Rigid	polyethylene
Chêneau and derivatives	France-Germany	J Cheneau	C: custom made	CAD/CAM - hand made	R: Rigid	polyethylene
Dynamic Derotating	Greece	N Vastatzidis	C: custom made	CAD/CAM - hand made	R: Rigid	polypropylene and aluminium
Lyon	France	P Stagnara			V: Very rigid	polymetacrylate and radioluscent duralumin
Milwaukee	USA	W Blount, A Schmidt			R: Rigid	polyethylene, alumin and steel
PASB	Italy	L Aulisa	C: custom made	Hand made	R: Rigid	polyethylene
Providence	USA	C d'Amato, B McCoy	C: custom made	CAD/CAM - hand made	R: Rigid	polyethylene
Rosemberger Sforzesco	USA Italy	R Rosemberger S Negrini, M Marchini	C: custom made	CAD/CAM - hand made	R: Rigid V: Very rigid	polyethylene copolyester ± radioluscent duralumin
SpineCor	Canada	C Coillard, C Rivard	P: prefabricated envelope	Prefabricated models	E: Elastic	elasthic tissue
TLI	The Netherlands	P Van Loon	P: prefabricated envelope	Prefabricated models	R: Rigid	polyethylene
TriaC	The Netherlands	AG Veldhuizen			L: Low Rigidity	soft plastic and metallic connections
Wilmington	USA	D MacEwen	C: custom made	Hand made	R: Rigid	polyethylene

the corresponding dodging site involves 4/5 of the surface of the concave side of the curve. Each of the remaining two pressure parts of the 3-point system presses on 1/5 of the surface of the concave side, which are the apexes of the neighboring curves. Dodging opposite the latter sites (might say, secondary curve or lesser curves) allows movement and active straightening of the curve. The brace does not hinder any of the three dodging areas, that is, the middle 4/5 of concave side and the 1/3 over and under the apex.

The mechanisms of Chêneau brace correction are: 1) passive mechanisms: convex to concave tissue transfer achieved by a 3-point system acting in multiple dimensions with the aim of curve hyper-correction, elongation, and unloading; derotation of the thorax; and bending; and 2) active mechanisms: vertebral growth acting as a corrective factor, asymmetrically guided respiratory movements of the rib cage, repositioning of the spatial arrangement of the trunk muscles to provide physiological action, and anti-gravitational effect.¹⁴

OUTCOMES

The brace is reported to obtain an average primary in brace correction of 41% (thoracic, lumbar, double) and a long-term correction of 14.2% thoracic, and 9.2% lumbar double curves: 5.5% thoracic and 5.6% lumbar. Also reported at the end of treatment is about 25% of Cobb-angle correction and, stabilization of about 23% (P value <0.05). Therefore, the Chêneau brace not only halts progression, but possibly improves the scoliotic curve.¹⁵

Chêneau brace derivatives

RIGO SYSTEM CHÊNEAU BRACE (RSCB)

Developed during the early 1990s, Rigo-Chêneau is basically a Chêneau type brace designed according to re-defined biomechanical principles and a new curve-pattern specific classification (Figure 1). The brace combines forces required to correct scoliosis in 3D.¹⁶ The blueprint of the brace is based on the classifica-

Anatomical Classification	Construction of the Envelope	Mechanism of Action	Plane of action	Brace Map Classification	Opening	Main indication	Initial Hours of prescription
A	CE	MA	P				
L: LSO	S: Symmetric	T: Three Point	3D: 3-dimensional	PRLST3D	posterior	single and double curves	full time/part time
L: LSO	A: Asymmetric	T: Three Point	Fr: Frontal	CRLATFr	anterior	single lumbar, thoracolumbar, thoracic curves	night time
T: TLSO	A: Asymmetric	T: Three Point	3D: 3-dimensional	CRTAT3D	anterior	single and double curves	full time
T: TLSO	A: Asymmetric	T: Three Point	FH: Frontal Horizontal	CRTATFH	posterior	single and double curves	full time
T: TLSO	A: Asymmetric	T: Three Point	3D: 3-dimensional	CVTAT3D	anterior	single and double curves	full time/part time
C: CTLSO	A: Asymmetric	E: Elongation	FH: Frontal Horizontal	CRCAEFH	posterior	single and double curves	full time/part time
L: LSO	A: Asymmetric	T: Three Point	3D: 3-dimensional	CRLAT3D	anterior	single lumbar/thoracolumbar curves	full time
T: TLSO	A: Asymmetric	T: Three Point	Fr: Frontal	CRTATFr	anterior	single and double curves	night time
L: LSO	A: Asymmetric	T: Three Point	Fr: Frontal	CRLATFr	anterior	single and double curves	full time/part time
T: TLSO	S: Symmetric	P: Push	3D: 3-dimensional	CVTSP3D	anterior	single and double curves	full time
T: TLSO	A: Asymmetric	M: Movement	3D: 3-dimensional	PETAM3D	NA	single and double curves	full time
L: LSO	S: Symmetric	T: Three Point	Sa: Sagittal	PRLSTSa	posterior	single and double curves	full time
T: TLSO	A: Asymmetric	T: Three Point	3D: 3-dimensional	PLTAT3D	NA	single and double curves	full time/part time
T: TLSO	A: Asymmetric	T: Three Point	FH: Frontal Horizontal	CRTATFH	anterior	single and double curves	full time/part time

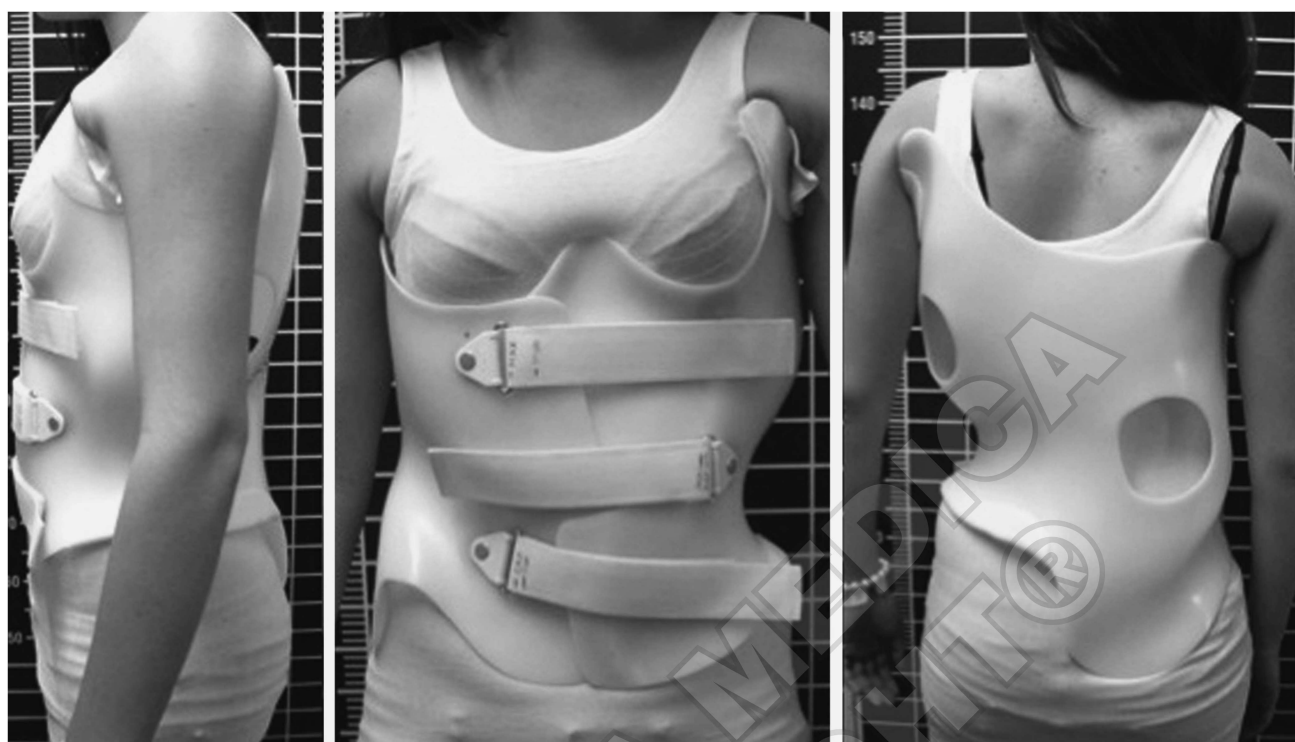


Figure 1.—Rigo Chêneau brace.

tion, which includes clinical as well as radiological criteria. The clinical criteria are utilized to differentiate four basic types: 1) imbalanced thoracic (A type); 2) true double (B type); 3) balanced thoracic and false double (C type); 4) single lumbar or thoracolumbar (E type). Radiological criteria are used to confirm the basic curve type and additionally diagnose nine different sub-types. Biomechanical principles are: 1) three-point systems; 2) pair of forces for derotation and counter-rotation; 3) breathing mechanics to prevent the morphological thoracic flat back; 4) sagittal physiological profile. The author has also generalized the use of the “open pelvis” design. It exists a CAD-CAM version (RSC®), used mostly in Germany.

Outcomes.—Initial reports indicated a 31.1% primary Cobb angle in brace correction and 22.2% primary torsion angle correction. At a follow-up of 16.8 months, 54% of curves were stable, 27% improved, and 19% progressed.¹⁷ In a further study, from a total of 106 braced cases out of which 97 were followed up, six cases (5.6%) ultimately underwent spinal fusion. A

worst case analysis brought the uppermost number of cases that could have undergone spinal fusion to 15 (14.1%), significantly lower to the 28% reported surgeries from a centre with the policy of non-conservative intervention.¹⁸ Recently, the in-brace correction of the Cobb angle has been improved: 53.7% for the main curve.¹⁹ In patients with long thoracic curves treated with an improved brace design (A1 type), the reported in-brace correction is 76.7% for the Cobb angle and 55.9% for the axial rotation.²⁰ End results from an independent group have shown that the Rigo System Chêneau brace provides excellent clinical results in the treatment of mild to moderate AIS.²¹

SCOLILOGIC® “CHÊNEAU LIGHT”

The ScoliOlogiC® “Chêneau light” was invented by Dr. Hans-Rudolf Weiss, and was presented and built in 2005,²² with the aim to make the brace lighter, finer, easier to wear, and by this, allowing a better quality of life for the patients with scoliosis under brace treatment.

Outcomes.—Weiss *et al.*, 2007, reported 51% correction of Cobb angle (Cobb angle in the whole group of patients was reduced by an average of 16.4°), 62% correction for lumbar and thoracolumbar curve pattern, 36% correction for thoracic scoliosis, and 50% correction for double-major curve pattern. The correction effect correlated negatively with age ($r=-0.24$; $P=0.014$), negatively with the Risser stage (-0.29 ; $P=0.0096$) and negatively with Cobb angle before treatment ($r=-0.43$; $P<0.0001$).²³ No end of treatment results are available at present time for this brace.²⁴

Dynamic derotating brace (DDB)

Developed in Athens, Greece, in the 1980s, the DDB is made of polypropylene with a soft foam polyethylene lining and opens posteriorly.²⁵ The DDB is a TLSO-type brace, featuring anti-rotatory blades that act as springs/anti-rotatory devices, maintaining constant correcting forces at the pressure areas of the brace while producing movements in opposite directions of the two halves of the brace (Figure 2). The derotating metal blades are attached to the rear side of the brace corresponding to the most protruding part of the thorax (hump) or the trunk of the patient. These blades become active when their free ends are placed underneath the opposite side of the

brace and the brace's straps are tightened. The forces applied by the blades are added to the side forces exerted by the brace, and changing of the backward angle of the blades modifies them.

OUTCOMES

The published reports detail an overall initial Cobb-angle correction of 49.54% and, at the 2-year follow-up, a correction of 44.10%. It was also reported that, overall, 35.70% of curves improved, while 46.42% were stable, and 7.83% worsened or increased. As far as the cosmesis (Angle Trunk Inclination, or ATI/hump) is concerned, the DDB improves the cosmetic appearance of the back in IS children with all but right-thoracic curves. The study on quality of life after conservative treatment of AIS using DDB with the Brace Questionnaire (BrQ), which is specific to brace treatment, revealed an influence on school activity and social functioning but not on general health perception, physical functioning, emotional functioning, vitality, bodily pain, self-esteem, or aesthetics.²⁶

Lyonnaise (Lyon) brace

Created by Pierre Stagnara in 1947, Allègre and Lecante modified the Lyon brace to its present form

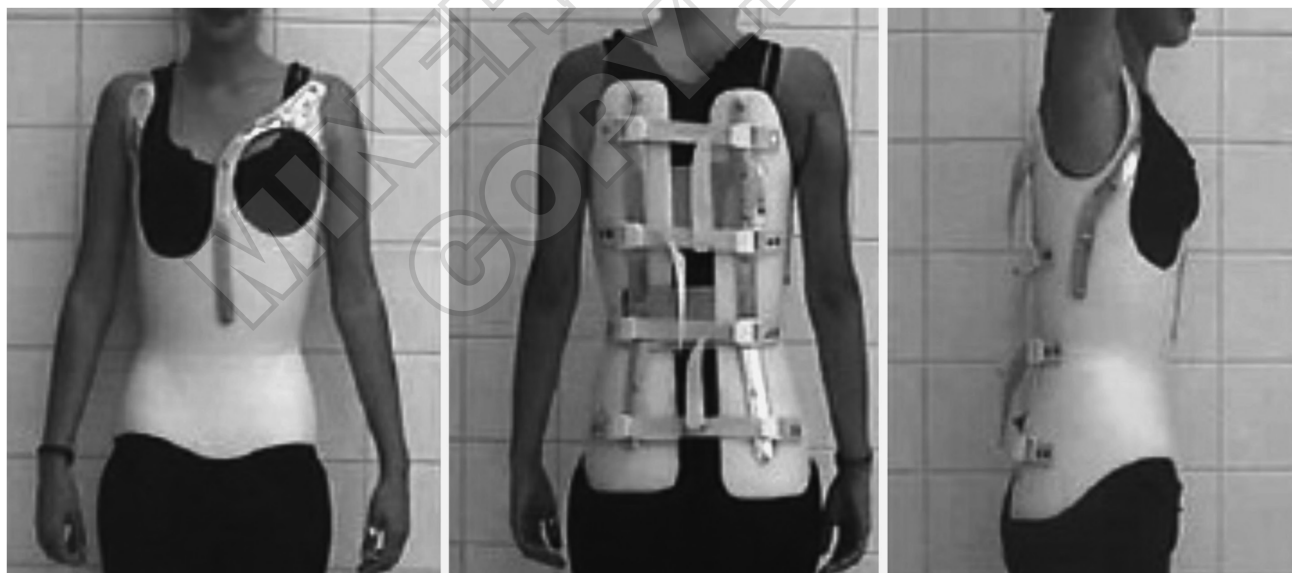

Figure 2.—Dynamic derotating brace.

using aluminium bars and plexidur (a high-rigidity material) in 1958.²⁷ An adjustable rigid brace without a neck ring, the bars of this brace are made of radioluscent duralumin, the faceplate and joint are made of high steel, and the thermo-malleable plastic is made of polymetacrylate (Figure 3). The treatment is based on two main principles: an initial plaster cast is meant to stretch the deep ligaments before the application of the Lyon brace and the subsequent application of the adjustable brace. The blueprint is based on Lenke's idiopathic scoliosis classification, with 14 design types. The indications for this brace are scoliosis patients who are 11-15 years old. This brace is not meant for younger patients in order to prevent tubular deformation of the thorax.

OUTCOMES

The reported results detail an effectivity index (results based on SRS-SOSORT treatment criteria two years after brace weaning) of 0.97 for lumbar curve, 0.88 for thoraco-lumbar curve, and 0.80 for thoracic curve. The Cobb-angle correction is reported for thoracic correction of 12%, for double major of 10% and 25%, for thoraco-lumbar of 24%, and for lum-

bar of 36%. Results are also obtained on cosmesis (hump in mm). The rib hump is better corrected than the Cobb angle, which is reduced by 1/3 at the thoracic level and by more than 50% at the lumbar level. The esthetical aspect is always better than the radiographs: in 1338 treated scoliotics, 67.19% were improved, 27.80% were stable, and 5% deteriorated.²⁷

Progressive action short brace (PASB)

Used since 1976 for the treatment of thoracolumbar and lumbar idiopathic curves, the PASB is a custom-made thoraco-lumbar-sacral orthosis (TLSO) brace of original design devised by Dr. Lorenzo Aulisa in Italy.²⁸ The PASB is only indicated for the treatment of thoraco-lumbar and lumbar curves, and is designed on the principle that a constrained spine's dynamics can achieve correction of a curve by inverting the abnormal load distribution during growth. The practical application of the biomechanical principles of the PASB is achieved through the following two operative phases. During a plaster-cast phase, which precedes the brace application, external forces are ex-

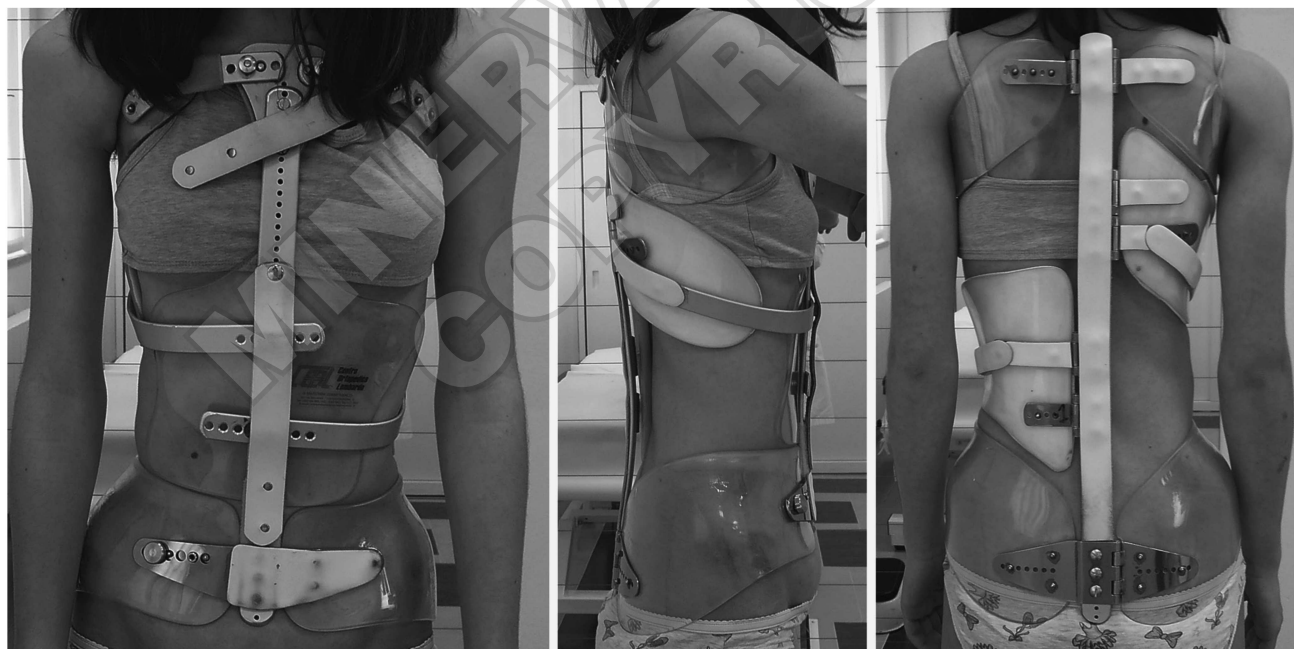


Figure 3.—Lyon brace.

erted to correct the deformity through elongation, lateral deflection, and derotation. This procedure allows transversal sections to be represented by asymmetric ellipsis. The finishing touch of the cast establishes the real geometry of the plastic brace. One, or sometimes two casts, in relation to the curve rigidity, are manufactured before switching to the custom-made polypropylene orthosis of the second phase of treatment (Figure 4).

OUTCOMES

Aulisa *et al.*, 2009, reported Cobb angle and Pedriole torsion angle readings of the treated thoracolumbar and lumbar curves. The pretreatment Cobb mean value was $29.3 \pm 5.16^\circ$, and the initial apical rotation was $12.7 \pm 6.14^\circ$. The immediate Cobb correction was $14.67 \pm 7.65^\circ$, and the apical rotation correction at follow up was $8.95 \pm 5.82^\circ$.

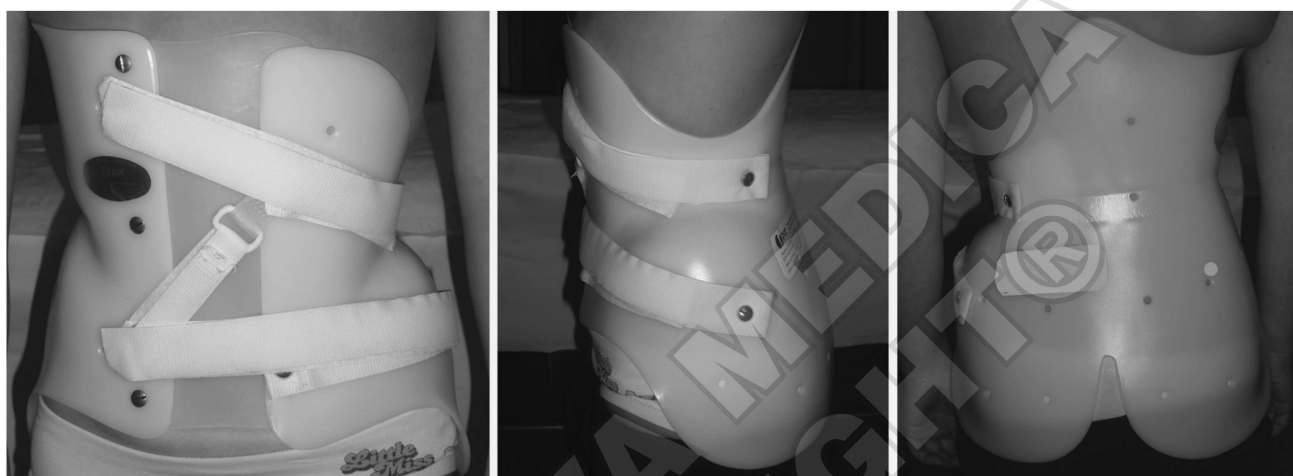

Figure 4.—PASB.

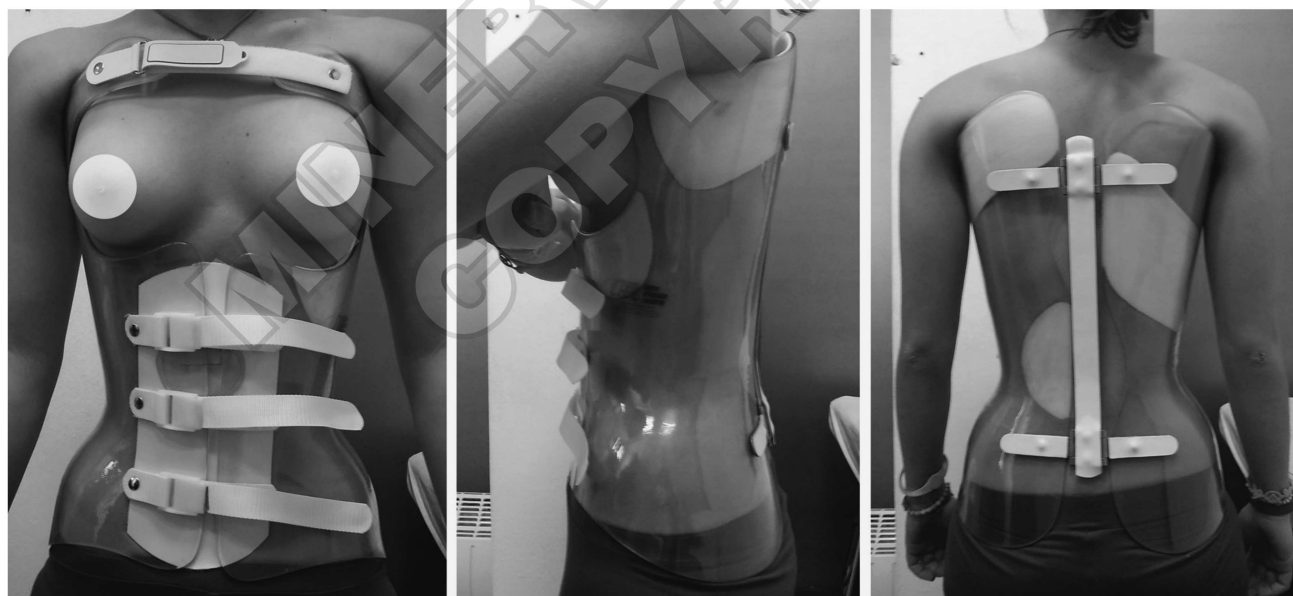


Figure 5.—Sforzesco brace.

Overall, curve correction was noted in 94% of patients, and curve stabilization in 6% of patients.²⁹

Sforzesco brace

Developed by Stefano Negrini and CPO Gianfranco Marchini in 2004, in Milan, Italy, based on the SPoRT concept (Symmetric, Patient-Oriented, Rigid, Three-Dimensional, Active), the Sforzesco brace combines characteristics of the Risser cast and the Lyon, Chêneau-Sibilla, and Milwaukee braces.³⁰ Its main action is to push scoliosis from the pelvis up, essentially to deflex, derotate, and restore the sagittal plane (3-dimensional action).^{30, 31} Published results have been superior to the Lyon brace and similar to the Risser cast with fewer side effects, making the Sforzesco brace useful for “worst cases,” according to authors (Figure 5). This brace is based on efficacy and acceptability correction principles: 1) efficacy: the active brace, in which the patient is allowed/encouraged to move freely; mechanical efficacy, which is achieved through pushes, escapes, stops, and drivers (with the last being a newly developed concept with this brace); versatility and adaptability; teamwork: MDs, CPOs, PTs, patient, and family; and compliance; and 2) acceptability: body design and minimal visibility; maximum freedom in the activities of daily life; assumption of responsibility; and a cognitive behavioural approach.

OUTCOMES

This brace is reported to be more effective than the Lyon brace after six months of treatment (38° Cobb curves on average): 80% improved and none worsened *vs.* 53% and 13%, respectively.³² It is as effective as the Risser plaster cast in achieving maximum correction after 18 months of treatment (40° Cobb average curve), and is more effective than the Risser cast + Lyon brace in treating curves over 45° Cobb reaching the end of growth (45°-58° Cobb), with better results in the thoracic curves without any sagittal plane worsening.³³ Further, this brace is able to improve esthetics in scoliosis patients. Recently, a controlled prospective study was published, showing that this brace is a suitable alternative for patients that reject any surgical intervention for IS above 45°. Patients joining treatment achieved a 10.4±10.7° Cobb improvement, with 61% who completed the treatment with less than 45°, and 15% with less the 35°.³⁴

TLI (thoracolumbar lordotic intervention) brace

A modified symmetric 30° Boston brace that ensures only forced lordosis at the thoracolumbar spine, the TLI brace is applied when the Cobb angle of at least one of the IS curves is ≥25° and kyphosis with or without a curve is <25° in the coronal plane. None



Figure 6.—TLI brace.

of the brace or casting techniques is based on sagittal forces only applied at the thoracolumbar spine. Applying the TLI brace in patients with scoliosis after forced lordosis at the thoracolumbar spine showed a radiological instantaneous reduction in both coronal curves of double major scoliosis (Figure 6).

OUTCOMES

The initial in-brace radiographs show a strong reduction of the Cobb angles in different curves in kyphosis and scoliosis groups (sagittal $P < 0.001$, pelvic obliquity $P < 0.001$). After one year of brace treatment in the scoliosis and kyphosis group, the measurements on radiographs made without brace revealed an improvement in all sagittal and coronal measurements.³⁵

TriaC™ brace

Developed by Dr. Albert Gerrit Veldhuizen in the Netherlands, "TriaC™" refers to the three Cs: comfort, control, and cosmesis.³⁶ The TriaC™ orthosis, which has a flexible coupling module connecting thoracic and lumbar parts, exerts a transverse force system consisting of an anterior progression force counteracted by a posterior force and torque, and acts on the vertebrae of a scoliotic spine. In the frontal plane, the force system in the TriaC™ brace is in accordance with the force system of conventional braces. However, in the sagittal plane, the force system acts only on the thoracic region. As a result, there is no pelvic tilt, which provides flexibility without affecting the correction forces during body motion. The introducers suggest that the inclusion criteria are: IS with a Cobb angle between 20° and 40° in skeletally immature scoliotics, with Risser 0–1 status, pre-menarche, post-menarche < 1 year, in primary thoracic apex between the 7th and 11th thoracic vertebra and primary lumbar apex between the 2nd and 5th lumbar vertebra, in flexible spinal column as evidenced by at least 40% correction on bending films. Some other studies suggest that the TriaC™ brace represents an alternative exclusively for the correction of lumbar curves.

OUTCOMES

An initial 22% correction is reported for the primary curves within the brace and 35% for the sec-

ondary curves. The improvement remained after bracing and in a mean follow-up of 1.6 years, as long as it was above a threshold of 20%. In 76% of the patients, there was control or net correction of IS curves. It is stated that the TriaC™ brace significantly alters the predicted natural history of AIS.³⁷

American braces

BOSTON BRACE

As the most frequently used scoliosis TLSO in North America, the Boston brace was originally developed by John Hall, MD, and William Miller, CO, at Boston Children's Hospital in 1972 to treat a patient with a lumbar curve who refused to use a Milwaukee brace. Their success with using just the pelvic girdle on other lumbar curves led them to extend the height of the plastic in treating thoracolumbar and thoracic curves, and to replace the superstructure with plastic axillary extensions (Figure 7). Miller and Hall sought to decrease the fabrication time involved in creating custom-molded braces, and created six prefabricated models based on the plaster model obtained during prior fittings for Milwaukee braces. Cost and fabrication time of the module were greatly reduced. The lower-profile, more cosmetically pleasing design was accepted more willingly by patients. Additional module sizes and variations were added to address a greater variety of curve presentations, and the developers of the Boston brace began an education program to train physicians and orthotists to use this revolutionary approach.

The Boston brace is a symmetrical, posterior opening design that incorporates apical pads that passively load the curves. Opposite of the thoracic pad, a window is cut in the orthosis that theoretically allows room for active truncal shift as well as improved ventilation. Like the Milwaukee, the Boston brace initially incorporated decreased lumbar lordosis, which hypothetically allowed for improved curve correction. Now, however, the brace typically includes 15° of lumbar lordosis in order to reduce the tendency to cause hypokyphosis. Unfortunately, many posterior-opening TLSOs are referred to as a "Boston brace" when, in fact, they are poor imitations. The original fitting involves body habitus measurement by an orthotist to determine the pre fabricated module. However, most braces today are



Figure 7.—Boston brace.

custom made based on body surface scanning and CAD-CAM construction.

Outcome: In one retrospective study about 295 patients, a comparison of follow-up with pre-brace values of major curves showed that 49% were unchanged, 43% achieved an improvement. Eleven percent of patients underwent surgery during the period of bracing; 1% had surgery during follow-up period.³⁸

CHARLESTON BENDING BRACE

As the first centrally fabricated nocturnal bracing system developed by Frederick Reed, MD, and Ralph Hooper, CO, in Charleston, South Carolina, in 1979, the Charleston bending brace was developed for a patient who refused to wear a full-time brace, and immediately found favor with many patients and their parents. Based on concepts derived from the Heuter-Volkman principle, wherein asymmetric vertebral loading can effect bone growth, the patient was generally molded supine in an aggressive, overcorrected, side-bending posture (Figure 8). The resultant orthosis is asymmetrical with an anterior opening and selective contact points, which results in greater in-brace correction than most other TLSO designs (also attributable to

the supine x-ray posture). Charlestons are most effective for single lumbar, thoracic, or thoracolumbar curves.

Outcome.—In a study fulfilling the SRS criteria, the Charleston brace showed to be effective in stabilizing or improving scoliosis progression in 84%, with 16% of progression.³⁹

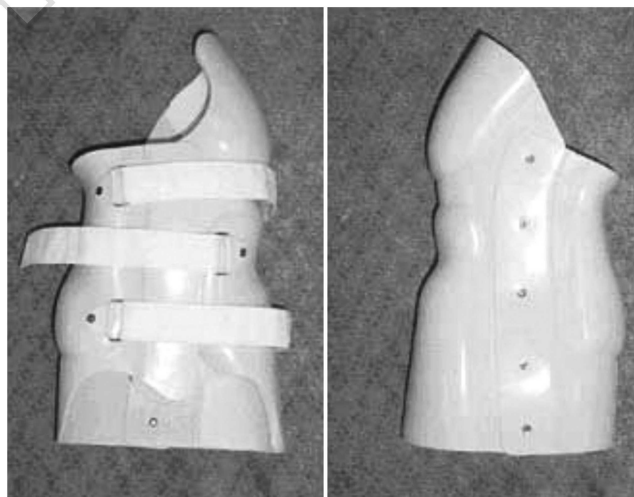


Figure 8.—Charleston brace.

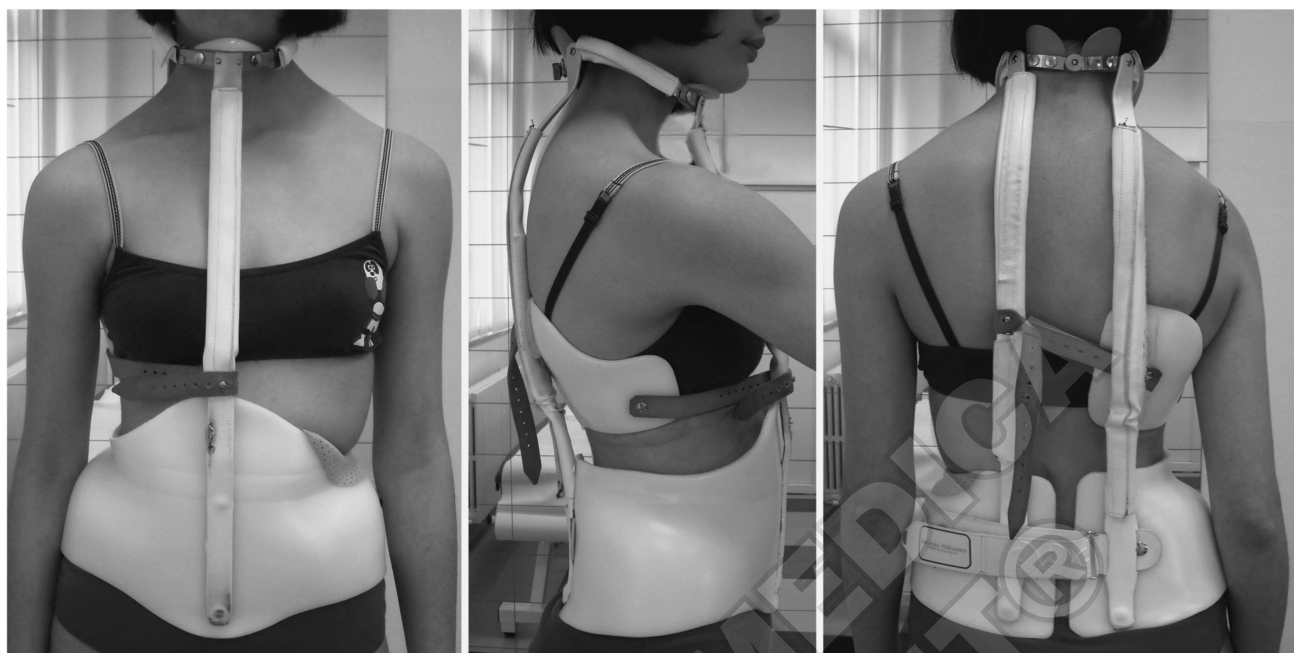


Figure 9.—Milwaukee brace.

MILWAUKEE BRACE

A CTLSO initially developed by Walter Blount and Albert Schmidt in Milwaukee, Wisconsin, circa 1945, the Milwaukee brace was initially used for post-operative immobilization of neuromuscular scoliosis patients. Later, the orthosis was thoroughly utilized and researched by Drs. Moe, Winter, and Lonstein of the Twin Cities group. The development of this orthosis represented a landmark in the treatment of scoliosis, as it became the first widely used removable orthosis to treat the disorder (Figure 9). Due to changing fashion concerns and the psychological and emotional impact of wearing a bulky CTLSO, the Milwaukee is now limitedly prescribed or worn. It is still, however, used to treat Scheuermann's kyphosis and high thoracic curves. Non-compliance with the Milwaukee has been high since its inception due to poor cosmesis.

The Milwaukee typically consists of a pelvic girdle (otherwise referred to as a pelvic module or LSO), a "superstructure," and a combination of corrective slings and pads that attach to the superstructure. The superstructure generally consists of a wide anterior aluminum bar, which allows for radiolucency, two posterior stainless steel bars, and a neck ring with

various throat and occipital pads or molds. Originally, a fixed chin rest was used to apply traction to the spine. However, due to mandibular problems and discomfort created by the chin rest, it was eventually replaced by a non-contact throat mold.

The Milwaukee brace has a symmetrical design with a posterior opening, and curve correction may consist of both passive and active mechanisms. For instance, thoracic or axillary slings apply direct, passive curve correction, while the throat molds or lateral pads allow for active correction as the patient intentionally moves away from these components. This method of active muscle correction by the patient was eventually shown to be fairly ineffective in scoliosis treatment, however, it was proven to be effective in the treatment of kyphosis.

Originally, the pelvic girdle was fabricated from form-fitting leather, but has been replaced by both high- and low-temperature thermoplastics, which are substantially easier and more cost-effective to fabricate. The girdle locks intimately onto the waist roll and, historically, lumbar lordosis was reduced in the girdle because it was theorized that this allowed for maximum scoliosis correction and spine mobility.

Outcomes.—According to Lonstein and Winter, 22% from a cohort of 1020 treated with a Milwau-



Figure 10.—Providence brace.

kee brace had operative intervention; this rate was higher in the patients who had a curve of more than 30 degrees at the time of bracing and in those who had a Risser sign of 0 or 1.⁴⁰ The main problem of this brace is compliance, due to its low acceptability, and for this reason today is often proposed for nighttime only.⁴¹

PROVIDENCE BRACE

Developed by Charles d'Amato and Barry McCoy of Children's Hospital of Rhode Island, in 1992, the Providence TLSO has surpassed the Charleston in frequency of use as a nocturnal bracing system due to its less aggressive and generally better tolerated design. The Providence incorporates an asymmetrical, anterior opening design, with selective contact points. Curve correction occurs through direct application of derotational and lateral forces, as opposed to the side-bending posture seen in the Charleston brace (Figure 10).

To fabricate the orthosis, the patient is placed on a polycarbonate measurement board that contains a series of vertically and horizontally labeled grid holes. Several padded bolsters are placed into the grid holes and adjusted to produce optimal curve correction and spinal realignment. In the past, after the appropriate bolster positions were recorded, the patient would be wrapped in plaster, and placed back on the acrylic

board where the bolsters would be re-adjusted back to their predetermined positions. As a result of technological changes, however, casting is unnecessary in most circumstances. Rather, the resultant bolster coordinates, in conjunction with other measurements and patient information are incorporated into a CAD/CAM system for orthosis fabrication.

Like the Charleston brace, the Providence has proven most effective in treating patients with flexible, single lumbar and thoracolumbar curves; however, it can be quite effective with thoracic and double curves.

Outcome.—According to a study fulfilling the SRS criteria, the rate of progression with this brace was high, with 60% of patients requiring surgery.⁴²

ROSENBERGER BRACE

The Rosenberg TLSO was one of the early true 3D designs in North America and has been limitedly used in Illinois, Iowa, and Virginia. Although it was originally developed by Richard Rosenberg, CO, at the University of Virginia in Charlottesville in 1983, it was more successfully redesigned and utilized by Wilton Bunch, MD, and Tom Gavin, CO, in Chicago, IL, in 1986. True pioneers in the development and application of spine biomechanics related to bracing, their method involved making a bivalve cast of the supine patient while reducing curves with translatory and derotational loads, which were subsequently incorporated into the TLSO. The brace is an asymmetrical, anterior opening design with selective contact and expansion areas and utilizes adjustable slings for optimal 3-point pressure system application.

Outcomes.—In a group of 71 patients treated with the Rosenberg brace, 61% failed (were fused or progressed) at the end of treatment.⁴³ The evidence from this study is very weak, and its main limit is the retrospective design

SPINECOR BRACE

The SpineCor brace is a distinctly unique strap-based, non-rigid orthosis that relies on patient movement to activate corrective effects. While use by orthopaedists has diminished, its popularity has grown amongst chiropractors. Developed by Christine Colliard, MD, and Charles Rivard, MD, at St. Justine Hospital, Montreal, Canada, in 1993, the SpineCor's

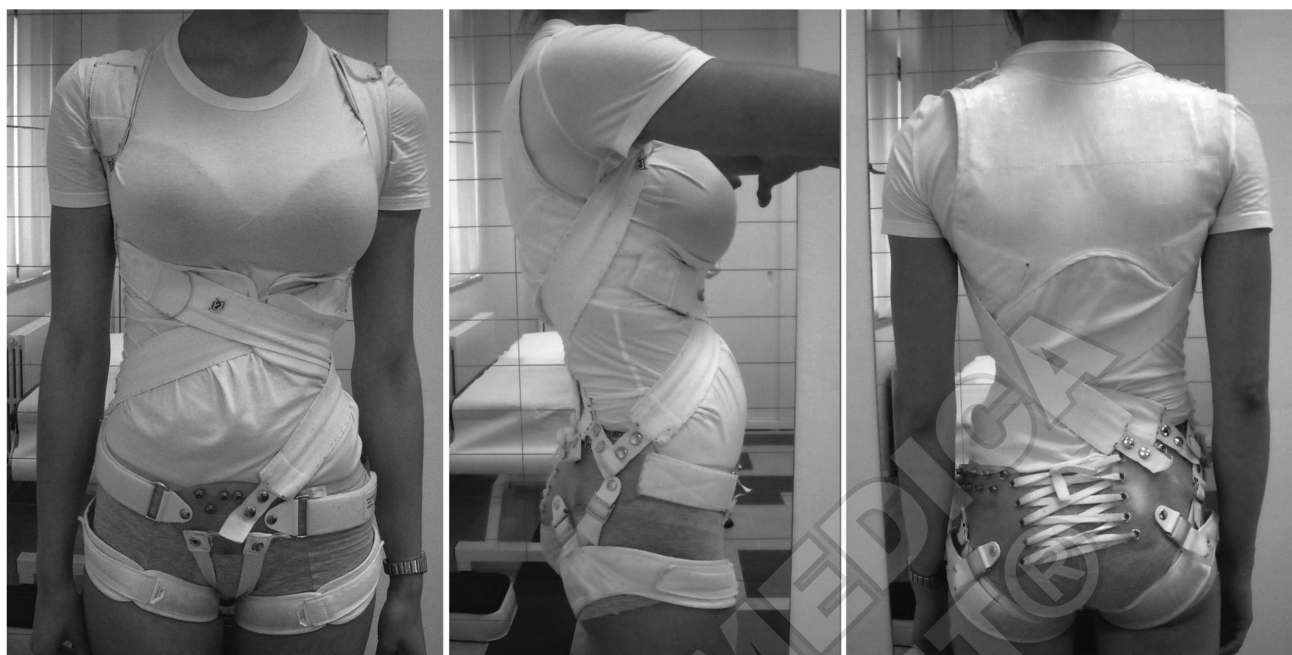

Figure 11.—SpineCor brace.

corrective principles differ significantly from traditional thermoplastic TLSOs since its action is based primarily on active corrective movement rather than passive force (Figure 11). This active correction attempts to correct spinal alignment by influencing postural disorganization, muscular dysfunction, and unsynchronized spinal growth.

The SpineCor is comprised of a thermoplastic pelvic section, thigh and crotch bands, a cotton bolero, and corrective elastic bands. A newer version uses spandex bike shorts for improved comfort. Adjustment to placement and tension of the bands is based on patient curve presentation. While originally prescribed by orthopedists and fitted by orthotists, poor initial response led to abandonment by most prescribers. Largely due to its ease of application and adjustment and patient acceptance, chiropractors now fit most SpineCor braces in North America.

Outcomes.—While this orthosis is reportedly well-tolerated and cosmetically acceptable, its efficacy for larger curves has been called into question. Nevertheless, in moderate curves, it showed to be effective. In a study respecting the SRS criteria, the SpineCor stabilized or improved 64% of patients, with only 18% of patients requiring surgery.⁴⁴

WILMINGTON BRACE

As the brace of choice at the A.I. DuPont/Ne-mours Children's Center in Wilmington, Delaware (and physicians who trained there), the Wilmington TLSO was developed by Dean MacEwen, MD, in 1969. The origins of the Wilmington TLSO trace back to a single patient who refused to wear a Milwaukee brace or Risser cast and sought a removable brace that could be concealed more easily. The underarm design of the Wilmington brace, made of orthoplast, not only offered improved cosmesis over the Milwaukee, but significantly reduced orthosis cost and fabrication time (Figure 12).

The Wilmington TLSO is a thermoplastic brace with a total contact, symmetrical design and an anterior opening, and was initially indicated to treat curves between 25° and 39° with apices at or inferior to T7. To fabricate the Wilmington, the practitioner molds the patient with plaster positioned supine on a Risser table. Simultaneously, either a series of straps or direct pushes by the practitioner reduce the scoliotic curves while the plaster is setting. After the cast has set, an X-ray is taken to determine the amount of curve reduction. If the physician is satisfied with the X-ray, the mold is filled

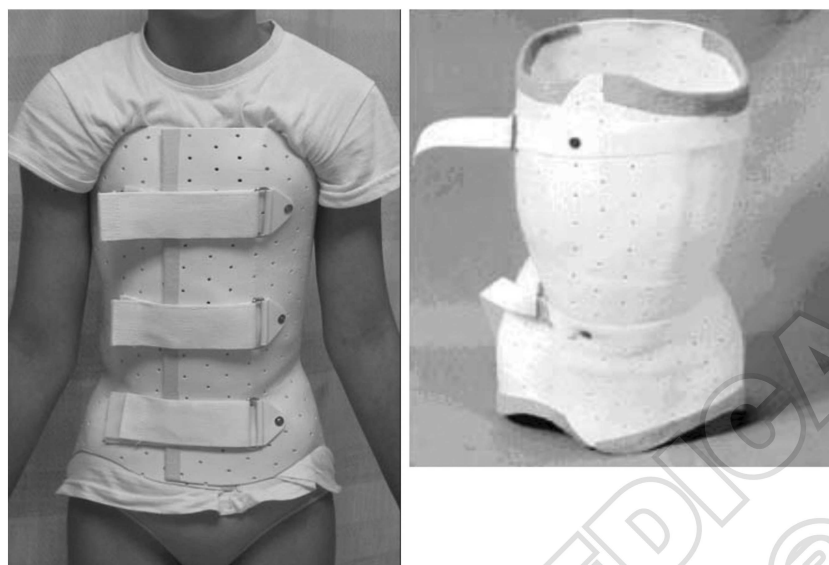


Figure 12.—Wilmington brace.

with plaster and the resultant positive mold modified. Thermoplastic is then molded directly over the positive mold and, after fitting the brace, the patient is X-rayed again.

Outcome.—According to a retrospective study, in a group of 91 patients, the progression rate was 17%, while the remaining population was stable.⁴⁵

Brace fabrication techniques and monitoring devices

Brace fabrication techniques have evolved, but the goals remain the same: a low-profile design that is tolerable and provides maximum curve reduction. Orthotists will utilize different fabrication methods within the same clinic, depending on the patient's abilities and presentation. The best method provides the model that allows the orthotist to fabricate the most appropriate orthosis.

Capturing the shape of the patient

Although there are different ways to capture the shape of the patient, care and skill are required throughout the fabrication process to ensure a well-designed and -fitting orthosis.

Plaster/fiberglass casting

Cotrel and Risser introduced the use of a casting frame, in which the patient is supine and under traction while corrective forces are applied to obtain a corrected model of the patient. Vertical frame, or bivalve casting, techniques were developed for clinics without access to a horizontal frame. After the model preparation, the plaster model is hand-modified and custom-TLSO-fabricated according to brace type.

Hand measurements

After noting that many plaster models appeared to be the same shape and size, Miller and Hall decided to try taking measurements in order to obtain a pre-fabricated symmetrical model. In the 1970s, Miller and Hall introduced a pre-fabricated symmetrical TLSO after taking circumferential, width (medial lateral), and depth (anterior posterior) measurements at specific landmarks and creating a symmetrical shape that provides corrective forces, supplemented by custom pads that were added according to brace principles. For the model preparation, an X-ray is required for brace design, and the orthosis is customized according to the blueprint.

Scanning and computer-aided design/computer-aided manufacturing (CAD/CAM)

CAD/CAM technology allows the orthotist to ascertain the individual shape of the patient in less time than casting and maintains an electronic copy of the patient's size and shape. Techniques, similar to those used for casting, are employed. Scanners can be stationary or handheld, laser (class 1 or 2), or white light. Commercially available stationary scanners are manufactured by Capturor, Creaform Inc., and Orten. Stationary scanners require more square footage and are limited in the scope of patients they can scan effectively because they are not portable. Commercially available handheld laser scanners include the O&P Scan from Rodin, which is a single camera, class one laser scanner; and the BioScanner from Biosculpture, which is a dual camera, class two laser scanner. Commercially available handheld white light scanners include the MD4 scanner (Rodin) and EVA scanner (Artec). Handheld scanners are able to capture most torso/body segment contours and are portable. The white light scanners are less expensive than laser scanners, but require more frequent calibration.

For the model preparation via CAD/CAM software, the scanner acts as a digital camera by capturing an image. To modify or manipulate that image, it is uploaded into CAD software like a photo would be uploaded to a program like Photoshop. Several manufacturers (e.g., Rodin4D, Biosculpture, Vorum, and Orten) sell software programs that allow for image elaboration and are unique to the orthotic and prosthetic profession, but are not specific to scoliosis. The image is then uploaded into the CAD software and modified according to specific bracing strategies. The X-ray and/or the 3D skeleton can be imported into the captured shape, and the model can be balanced for systems based on symmetry or shifted for asymmetrical protocols. Pads or pushes can be built into the CAD model, much like they would be for the hand-modified models. Time lines can be drawn and the finished brace shape reviewed.

Once the model is modified, the file is sent to a carver to have the positive model created. Plastic is then vacuum formed over the foam model, trimmed, smoothed, and ready for the initial fitting. The cost for this technology is US\$ 15,000-40,000, depending on the type of scanner, accessories (e.g., updated laptops), type of software, and licensing fees.

Future of fabrication with CAD/CAM

Software is currently being developed that will allow the orthotist to simulate a brace fitting prior to fabrication. Scans and X-rays will be imported as described previously, and a virtual patient will be created by the software. The orthotist will have the option of modifying a model or allowing the computer to create the most effective design to reduce the curve. Either way, a simulator will allow the virtual brace to be fitted on the virtual patient to test the results. The design can be adjusted to improve results prior to fitting the patient.

Fabrication material

Plastics are available in various thicknesses and rigidity, and a thinner, more rigid plastic may be selected over a thicker, more flexible plastic for cosmetic reasons. However, care must be taken to ensure the plastic is strong enough not to deform or fatigue over time. Reinforcements are sometimes added in areas where the forces on the spine are greatest.

Adjustments after fitting

Review of the in-brace X-ray is commonly accepted as a means to evaluate the patient's response as well as brace construction. Making accurate and effective adjustments during the first fitting maximizes the brace's effectiveness. One method of X-ray analysis, termed "the blueprint", which was first discussed by Watts and updated by Emans, provided orthotists with step-by-step procedures regarding X-ray analysis and brace fabrication. After the initial fitting, in brace X-ray provides indication about the correction, pads to be added and balance. More recently, Rigo detailed a bracing classification system based on X-ray analysis.

In-house fabrication – Central fabrication facilities

Many facilities have their own lab in which they fabricate the orthosis from start to finish. These can be internal or external to the facility, but the key elements are strong relationships and teamwork.

Other facilities use specialized fabrication facilities called central fabrication. The extent of fabrication depends on the orthotist and the capabilities of the lab.

Some central fabrication facilities specialize in spinal brace fabrication; however, most offer a wide range of fabrication capabilities. Central fabrication facilities specializing in scoliosis orthoses are Boston Brace, Spinal Technologies, Rodin4d, and SpineCorporation.

Regardless of where the orthosis is fabricated, the treating orthotist is responsible for the shape capture, design, fitting, and follow-up adjustments.

Monitors

Brace compliance has always been a challenge, and lower profile, lighter weight orthoses have been developed in the hopes of improving compliance. In a recent study showing the importance of compliance to bracing success, Negrini provided a model of implementing monitors in the clinical setting. Monitors eliminate the need to estimate wear by parents/patients and to become aware of habits leading to poor compliance. It is important to make sure the patient understands that the monitor is there to help determine if they are having difficulty adhering to the wear schedule so it can be addressed. By identifying the barriers, the team can develop successful strategies.

Manufacturers of commercially available thermal sensors include Tidbit, iButton, Cricket, and Micro-sensor. The Tidbit and iButton, which are used in various industries and are a volume product, which keeps their cost relatively low, use a single thermometer, meaning only the internal temperature of the brace is recorded. The Cricket, which was developed specifically for monitoring brace wear, has two thermometers for recording both the internal and ambient temperatures. Costs range from US\$ 50-160 for monitors, and from US\$ 40-2600 for readers.

Commonly, thermal sensor features have the ability to set the frequency of reads, use an internal non-rechargeable battery, and require a reader to download the data and software to interpret the downloaded data into a clinically relevant report.

The ISICO group has developed an algorithm that is available online at no cost.⁴⁶ Practitioners log in and copy the raw data into their program and the results are provided in a report showing average hours worn and average hours worn per day and by month. The Cricket data downloads into an Excel sheet, showing average hours worn and what hours during the 24-hour cycle the brace is worn.

The output report needs to be clinically relevant and in a format that resonates with the patients and families. Downloads need to be seamless and quick so that the clinic can run smoothly. Donzelli *et al.* showed referred compliance to be very similar to real one, with an average of more than 20 h per day.⁴⁶ This is a key point since a significant positive association between hours of brace wear and rate of treatment success has been demonstrated thanks to brace monitors.²

Experience with monitoring brace wear helps orthotists learn the type of reports patients and families need to assist in improving and maintaining compliance. Future studies should be required to report compliance in order to formulate conclusions.

Conclusions

Bracing has proven efficacy in reducing the need for surgery in IS patients, and it decreases the aesthetic impact of deformity. Many different kind of braces are available worldwide, and different techniques exist to build them properly. The SOSORT guidelines about brace management are useful to ensure patients are treated by trained doctors and orthotists. The role of exercises as possible adjunctive treatment to increase efficacy of bracing has been suggested and is under scrutiny.⁴⁷⁻⁵² The possibility of monitoring actual compliance through the use of thermal sensors is a real revolution in the field that will greatly help experts and, thereby, patients.

References

1. Negrini S, Aulisa AG, Aulisa L, Circo AB, de Mauroy JC, Durmala J *et al.* 2011 SOSORT Guidelines: Orthopaedic and Rehabilitation Treatment of Idiopathic Scoliosis During Growth. *Scoliosis* 2012;7:3.
2. Weinstein SL, Dolan LA, Wright JG, Dobbs MB. Effects of bracing in adolescents with idiopathic scoliosis. *N Engl J Med* 2013;369:1512-21.
3. Negrini S, Minozzi S, Bettany-Saltikov J, Zaina F, Chockalingam N, Grivas TB *et al.* Braces for idiopathic scoliosis in adolescents. *Cochrane Database Syst Rev* 2010;1:CD006850.
4. Negrini S, Minozzi S, Bettany-Saltikov J, Zaina F, Chockalingam N, Grivas TB *et al.* Braces for idiopathic scoliosis in adolescents. *Spine (Phila Pa 1976)* 2010;35:1285-93.
5. Bunge EM, Habbema JD, de Koning HJ. A randomised controlled trial on the effectiveness of bracing patients with idiopathic scoliosis: failure to include patients and lessons to be learnt. *Eur Spine J* 2010;19:747-53.
6. Bunge EM, de Bekker-Grob EW, van Biezen FC, Essink-Bot

- ML, de Koning HJ. Patients' preferences for scoliosis brace treatment: a discrete choice experiment. *Spine (Phila Pa 1976)* 2010;35:57-63.
7. Rigo M, Negrini S, Weiss HR, Grivas TB, Maruyama T, Kotwicki T. SOSORT consensus paper on brace action: TLSO biomechanics of correction (investigating the rationale for force vector selection). *Scoliosis* 2006;1:11.
 8. Negrini S, Aulisa AG, Aulisa L, Circo AB, de Mauroy JC, Durmala J *et al.* 2011 SOSORT guidelines: Orthopaedic and Rehabilitation treatment of idiopathic scoliosis during growth. *Scoliosis* 2012;7:3.
 9. Richards BS, Bernstein RM, D'Amato CR, Thompson GH. Standardization of criteria for adolescent idiopathic scoliosis brace studies: SRS Committee on Bracing and Nonoperative Management. *Spine* 2005;30:2068-75; discussion 2076-7.
 10. Negrini S, Grivas TB, Kotwicki T, Rigo M, Zaina F. Guidelines on "Standards of management of idiopathic scoliosis with corrective braces in everyday clinics and in clinical research": SOSORT Consensus 2008. *Scoliosis* 2009;4:2.
 11. Negrini S, Zaina F, Atanasio S. BRACE MAP, a proposal for a new classification of braces. *Stud Health Technol Inform* 2008;140:299-302.
 12. Cheneau J. Corset-Cheneau. Manuel d'Orthopédie des scolioses suivant la technique originale. Paris: Frison Roche; 1994.
 13. Kotwicki T, Pietrzak S, Szulc A. Three-dimensional action of Cheneau brace on thoracolumbar scoliosis. *Stud Health Technol Inform* 2002;88:226-9.
 14. Kotwicki T, Cheneau J. Biomechanical action of a corrective brace on thoracic idiopathic scoliosis: Cheneau 2000 orthosis. *Disabil Rehabil Assist Technol* 2008;3:146-53.
 15. Zaborowska-Sapeta K, Kowalski IM, Kotwicki T, Protasiewicz-Faldowska H, Kiebzak W. Effectiveness of Cheneau brace treatment for idiopathic scoliosis: prospective study in 79 patients followed to skeletal maturity. *Scoliosis* 2011;6:2.
 16. Rigo MD, Villagrasa M, Gallo D. A specific scoliosis classification correlating with brace treatment: description and reliability. *Scoliosis* 2010;5:1.
 17. Rigo M, Quera-Salva G, Puigdevall N, Martinez M. Retrospective results in immature idiopathic scoliotic patients treated with a Cheneau brace. *Stud Health Technol Inform* 2002;88:241-5.
 18. Rigo M, Reiter C, Weiss HR. Effect of conservative management on the prevalence of surgery in patients with adolescent idiopathic scoliosis. *Pediatr Rehabil* 2003;6:209-14.
 19. Rigo M, Gallo D. In-brace correction of the Cobb angle with RSC-CAD CAM compared with 'hand made' from the original author. *Scoliosis* 2010;5(Suppl 1):O68.
 20. Rigo M, Gallo D. A new RSC brace design to treat single long thoracic scoliosis. Comparison of the in-brace correction in two groups treated with the new and the classical models. *Scoliosis* 2009;4(Suppl2):O46.
 21. Ovadia D, Eylon S, Mashiah A. Factors associated with the success of the Rigo System Cheneau brace in treating mild to moderate adolescent idiopathic scoliosis. *J Child Orthop* 2012;6:327-31.
 22. Weiss HR, Werkmann M, Stephan C. The ScoliOlogiC "Cheneau light" brace--does the reduction of material affect the desired correction? *Stud Health Technol Inform* 2006;123:250-4.
 23. Weiss HR, Werkmann M, Stephan C. Correction effects of the ScoliOlogiC(R) "Cheneau light" brace in patients with scoliosis. *Scoliosis* 2007;2:2.
 24. Weiss HR, Werkmann M. "Brace Technology" Thematic Series - The ScoliOlogiC(R) Cheneau light brace in the treatment of scoliosis. *Scoliosis* 2010;5:19.
 25. Grivas TB, Vasiliadis E, Chatziargiropoulos T, Polyzois VD, Gatos K. The effect of a modified Boston brace with anti-rotatory blades on the progression of curves in idiopathic scoliosis: aetiological implications. *Pediatr Rehabil* 2003;6:237-42.
 26. Grivas TB, Vasiliadis ES. Cosmetic outcome after conservative treatment of idiopathic scoliosis with a dynamic derotation brace. *Stud Health Technol Inform* 2008;135:387-92.
 27. de Mauroy JC, Lecante C, Barral F. "Brace Technology" Thematic Series - The Lyon approach to the conservative treatment of scoliosis. *Scoliosis* 2011;6:4.
 28. Aulisa AG, Mastantuoni GG, Laineri MM, Falciglia FF, Giordano MM, Marzetti EE *et al.* Brace technology thematic series: the progressive action short brace (PASB). *Scoliosis* 2012;7:6.
 29. Aulisa AG, Guzzanti V, Galli M, Perisano C, Falciglia F, Aulisa L. Treatment of thoraco-lumbar curves in adolescent females affected by idiopathic scoliosis with a progressive action short brace (PASB): assessment of results according to the SRS committee on bracing and nonoperative management standardization criteria. *Scoliosis* 2009;4:21.
 30. Negrini S, Marchini G, Tessadri F. "Brace technology" thematic series - The Sforzesco and Sibilla braces, and the SPoRT (Symmetric, Patient oriented, Rigid, Three-dimensional, active) concept. *Scoliosis* 2011;6:8.
 31. Negrini S, Marchini G, Tomaello L. The Sforzesco brace and SPoRT concept (Symmetric, Patient-oriented, Rigid, Three-dimensional) versus the Lyon brace and 3-point systems for bracing idiopathic scoliosis. *Stud Health Technol Inform* 2006;123:245-9.
 32. Negrini S, Marchini G. Efficacy of the symmetric, patient-oriented, rigid, three-dimensional, active (SPoRT) concept of bracing for scoliosis: a prospective study of the Sforzesco versus Lyon brace. *Eura Medicophys* 2007;43:171-81.
 33. Negrini S, Zaina F, Negrini F, Marchini G, Aulisa AG. Sforzesco brace (SPoRT Concept) versus Risser cast in adolescent idiopathic scoliosis treatment: similar efficacy, with reduced spinal side effects for the brace. In: O'Brien JP, Hawes MC, editors. 4th International Conference on Conservative Management of Spinal Deformities; 2007 13-16 May 2007; Boston: SOSORT (Society on Scoliosis Orthopaedic and Rehabilitation Treatment); 2007.
 34. Lusini M, Donzelli S, Minnella S, Zaina F, Negrini S. Brace treatment is effective in idiopathic scoliosis over 45°: an observational prospective cohort controlled study. *Spine J* 2013 [Epub ahead of print].
 35. van Loon PJ, Roukens M, Kuit J, Thunnissen FB. A new brace treatment similar for adolescent scoliosis and kyphosis based on restoration of thoracolumbar lordosis. Radiological and subjective clinical results after at least one year of treatment. *Scoliosis* 2012;7:19.
 36. Veldhuizen AG, Cheung J, Bulthuis GJ, Nijenbanning G. A new orthotic device in the non-operative treatment of idiopathic scoliosis. *Med Eng Phys* 2002;24:209-18.
 37. Bulthuis G, Veldhuizen A, Nijenbanning G. Clinical effect of continuous corrective force delivery in the non-operative treatment of idiopathic scoliosis: a prospective cohort study of the TriaC-brace. *Eur Spine J* 2008;17:231-9.
 38. Emans JB. Scoliosis: diagnosis and current treatment. *Women Health* 1984;9:81-102.
 39. Lee CS, Hwang CJ, Kim DJ, Kim YH, Kim YT, Lee MY *et al.* Effectiveness of the Charleston night-time bending brace in the treatment of adolescent idiopathic scoliosis. *J Pediatr Orthop* 2012;32:368-72.
 40. Lonstein JE, Winter RB. The Milwaukee brace for the treatment of adolescent idiopathic scoliosis. A review of one thousand and twenty patients. *J Bone Joint Surg Am* 1994;76:1207-21.
 41. Maruyama T, Takeshita K, Kitagawa T. Milwaukee brace today. *Disabil Rehabil Assist Technol* 2008;3:136-8.
 42. Janicki JA, Poe-Kochert C, Armstrong DG, Thompson GH. A comparison of the thoracolumbosacral orthoses and providence orthosis in the treatment of adolescent idiopathic scoliosis: results using the new SRS inclusion and assessment criteria for bracing studies. *J Pediatr Orthop* 2007;27:369-74.
 43. Spoonamore MJ, Dolan LA, Weinstein SL. Use of the Rosen-

- berger brace in the treatment of progressive adolescent idiopathic scoliosis. *Spine* 2004;29:1458-64.
44. Coillard C, Circo AB, Rivard CH. Effectiveness of the SpineCor brace based on the standardized criteria proposed by the S.R.S. for adolescent idiopathic scoliosis – up to date results. In: de Mauroy JC, editor. 6th International Conference on Conservative Management of Spinal Deformities; 2009; Lyon; 2009. p. saa15.
 45. Gabos PG, Bojescul JA, Bowen JR, Keeler K, Rich L. Long-term follow-up of female patients with idiopathic scoliosis treated with the Wilmington orthosis. *J Bone Joint Surg Am* 2004;86-A:1891-9.
 46. Donzelli S, Zaina F, Negrini S. In defense of adolescents: They really do use braces for the hours prescribed, if good help is provided. Results from a prospective everyday clinic cohort using thermobrace. *Scoliosis* 2012;31:1.
 47. Zaina F, Negrini S, Atanasio S, Fusco C, Romano M, Negrini A. Specific exercises performed in the period of brace weaning can avoid loss of correction in Adolescent Idiopathic Scoliosis (AIS) patients: Winner of SOSORT's 2008 Award for Best Clinical Paper. *Scoliosis* 2009;4:8.
 48. Romano M, Minozzi S, Bettany-Saltikov J, Zaina F, Chockalingam N, Kotwicki T *et al.* Exercises for adolescent idiopathic scoliosis. *Cochrane Database Syst Rev* 2012;8:CD007837.
 49. Negrini S, Negrini A, Romano M, Verzini N, Parzini S. A controlled prospective study on the efficacy of SEAS.02 exercises in preparation to bracing for idiopathic scoliosis. *Stud Health Technol Inform* 2006;123:519-22.
 50. Negrini S, Fusco C, Minozzi S, Atanasio S, Zaina F, Romano M. Exercises reduce the progression rate of adolescent idiopathic scoliosis: results of a comprehensive systematic review of the literature. *Disabil Rehabil* 2008;30:772-85.
 51. Smania N, Picelli A, Romano M, Negrini S. Neurophysiological basis of rehabilitation of adolescent idiopathic scoliosis. *Disabil Rehabil* 2008;30:763-71.
 52. Romano M, Minozzi S, Zaina F, Saltikov JB, Chockalingam N, Kotwicki T *et al.* Exercises for adolescent idiopathic scoliosis: a Cochrane systematic review. *Spine (Phila Pa 1976)* 2013;38:E883-93.

Acknowledgements.—The authors wish to thank Alessandra Salimbene from SR Comunicazione (www.srcomunicazione.it) for helping in formatting images.

Conflicts of interest.—The authors certify that there is no conflict of interest with any financial organization regarding the material discussed in the manuscript.