

Role of physical exercise in the treatment of mild idiopathic adolescent scoliosis

Review of the literature

A. NEGRINI, N. VERZINI, S. PARZINI, A. NEGRINI, S. NEGRINI*

Physical exercise therapy (or kinesitherapy) is a program of physical exercises, specifically developed by a well trained physiotherapist, with the main aim of: preventing the aggravation of the deformity, in mild scoliosis; helping the brace and counteracting its side effects, in moderate scoliosis. The aim of this paper is to review the literature to ascertain which of the impairments and disabilities caused by scoliosis could be prevented or reduced by physical exercise. An up-to-date knowledge of these aspects is needed in order to decide: whether there is an adequate theoretical basis for or against the use of kinesitherapy; whether or not the practice of leisure time sporting activities should be allowed. It is essential to identify which categories of physical exercises (*i.e.* mobilization or stabilization; strengthening or stretching; etc.) should be avoided because they could be detrimental and which should be intensified because they could be useful. Knowledge emerging from scientific research data, according to the review of the literature proposed in this paper, confirms that physical exercise: prevents or reduces disabilities of scoliotic patients; facilitates the neutralization of postural deficits to produce, as a consequence, a stationary or regressive curve. The use of appropriate kinesitherapy to increase postural stability is theoretically correct, although a more accurate and detailed risk/benefits analysis is needed.

Key words: **Scoliosis, therapy - Exercise - Posture.**

In the treatment of common vertebral pathologies (ranging from low back pain to idiopathic scoli-

Centro Scoliosi, Vigevano (PV), Italy
*Unità di Riabilitazione e Recupero Funzionale
Fondazione Don Carlo Gnocchi
ONLUS, IRCCS, Milano, Italy

osis) we are actually facing many changes: evidence is growing that some approaches until now considered standard could, in many cases, be useless if not dangerous. This is true of rest in low back pain,^{1, 2} or surgical treatments in disc prolapse.^{1, 2}

In the case of structural idiopathic adolescent scoliosis, physical exercise is employed as a form of therapy only in certain countries (mainly in the Latin world, *i.e.* Italy, France, Spain, but also in Germany³⁻¹⁵); in other regions where this kind of treatment is practiced it has been criticized and rejected by many authors. For many years this was also true of orthopedic treatment with braces, but there is now growing evidence suggesting the usefulness of this form of treatment.¹⁶ Results have emerged in favor of physical exercise too,^{5, 6, 17} but these are not yet unequivocal and this form of treatment is still under debate.

First of all it is necessary to clarify a number of basic concepts that will be debated in this paper.

Scoliosis

Definitions

Scoliosis is a three dimensional deviation of the spine that causes a curve that can be seen and measured using Cobb's method on an antero-posterior

Submitted for publication July 27, 2001.
Accepted August 22, 2001.

Address reprint requests to: S. Negrini - Fondazione Don Gnocchi - Via Capecelatro, 66 - 20148 Milano (Italy). E-mail: snegrini@dongnocchi.it.

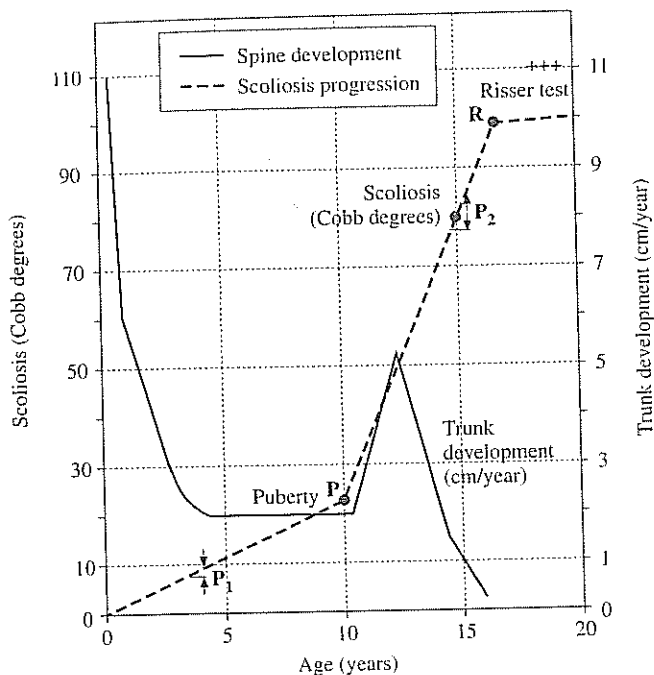


Fig. 1.—Graph of Duval-Beaupère.¹⁶ The aggravation of idiopathic scoliosis is rapid between the points "P" (beginning of puberty) and "R" (Risser sign positive, *i.e.* beginning of the ossification of the iliac crest). This moment precedes the menarche and coincides with the pubertal growth spurt.

radiograph.¹³ The mere presence of this curve does not automatically indicate the presence of a deformity (structural curve).

It is possible to differentiate a structural curve from a postural one by identifying the hump during Adam's test:¹⁸⁻²⁰ looking from behind at the patient who is bending forward it is possible to detect an elevation of one side of the trunk, usually on the convex side of the radiographic curve, that can be measured using Bunnel's "Scoliometer".^{18, 21} This hump is due to the presence of vertebral rotation, a characteristic feature of the deformity that can be seen and measured with Perdriolle's "Torsiometer" on an antero-posterior radiograph.²²

Seventy per cent of scolioses are considered to be idiopathic.¹⁴ Diagnosis in this case is by exclusion, as idiopathic means that we do not know the origin of the curve. In other cases it is possible to identify a disease that can justify the deformity, such as malformations, neurological or genetic diseases, cancer, trauma, etc.¹³

Idiopathic scoliosis has been divided, according to

the age of the patient at the time of detection of the condition, into four types: infantile, juvenile, adolescent and adult. The most common type is the adolescent one, characterized by a sudden aggravation during the growth spurt (Fig. 1).²³

While postural scoliosis is very common, the prevalence rates for adolescent idiopathic structural curves in school children are:¹⁸⁻²⁰

- 10 Cobb degrees or more: 1.5-1.7%;
- 20 Cobb degrees or more: 0.2%;
- 40 Cobb degrees or more: 0.02%.

Clinical decisions are based on an accurate prognosis, which is obtained in each patient mainly on the basis of the residual potential of growth and the results of both clinical and radiographic examination:¹²⁻¹⁴ consequently a clinical classification of the single patient, to some extent coinciding with the radiographic one, can be summarized as follows:

- mild: less than 20 Cobb degrees;
- moderate: between 20 and 45 Cobb degrees;
- severe: more than 45 Cobb degrees.

On the basis of this clinical classification (with mild variations of their boundaries), in most centers for scoliosis treatment in the Latin world (*i.e.* Italy, France and Spain) treatment is planned as follows:⁸⁻¹⁴

- mild: kinesitherapy and look-out;
- moderate: brace and/or cast and kinesitherapy;
- severe: surgery.

Physical exercise for scoliosis

Definitions

Physical exercise therapy (or kinesitherapy) is a program of physical exercises, specifically developed by a well trained physiotherapist, with the main aim of:

- preventing the aggravation of the deformity, in mild scoliosis;
- helping the brace and counteracting its side effects, in moderate scoliosis.

In this respect, kinesitherapy for scoliosis is considered a form of specific training and is generally proposed in sessions of 45 to 60 minutes, two to four times a week. Physical exercises can also have other aims, as it will be discussed in this paper.

It is not possible to describe a single program of exercises, as programs are usually personalized (*i.e.*

focused on the needs of individual patients) although they can be applied on a group basis (4 to 6 patients per group). Moreover, these programs frequently vary from one institute to another. In any case, as we will show in this paper, it is more useful to identify kinesitherapeutic aims which correspond to certain categories of physical exercise rather than to discuss individual programs.

Advice about leisure time and school sporting activities is commonly given, according to what is considered useful or harmful in the training of the patient. In this paper the general term "physical activities" is taken to embrace both sport and kinesitherapy.

As we mentioned above, only inconclusive results have so far been published,^{5, 6, 17} and kinesitherapy is still a subject for debate. Critics base their mistrust of any form of physical exercise as a therapy for idiopathic scoliosis on its origins: initially, it was the province largely of practitioners who intervened both generally (more as a calisthenic intervention than as a therapeutic one) and specifically on the basis of some unproven hypothesis which, furthermore, had no real scientific basis.^{25, 26} Both these types of pseudotherapy tended to aggravate scoliotic curves, principally as a result of mobilization of an inadequately supported spine.^{7, 9, 12} Moreover, there is a lack of good research in Indexed Journals, and the only paper usually cited is a preliminary study.²⁷ In this way, many orthopedic surgeons and physicians advised young scoliotic patients against both physical exercise and sport.²⁸

It must be noted that physical exercise treatments differ according to the therapeutic aims on which the approach to the patient and his impairment is based; the same is true of pharmacological treatments which differ as regards the molecule used for the patient and his disease. It is possible, therefore, that while one kind of physical exercise must be avoided by the scoliotic patient, another, as well as not being dangerous, might in fact be considered useful and thus recommended.

In our centers we have been using for many years now, physical exercise to treat patients affected by mild structural adolescent idiopathic scoliosis.^{11, 29} Since the first results were published⁷ the program has been upgraded: in fact, developments in the literature in the last 30 years^{7, 9} have identified more and more impairments and disabilities due to idiopathic scoliosis that can be modified by physical exercise treatment.

Aim

The aim of this paper is to review the literature to ascertain which of the impairments and disabilities caused by scoliosis could be prevented or reduced by physical exercise. An up-to-date knowledge of these aspects is needed in order to decide:

- whether there is an adequate theoretical basis for or against the use of kinesitherapy;
- whether or not the practice of leisure time sporting activities should be allowed.

Moreover, having established the usefulness of kinesitherapy (it is already considered established in some parts of the world), it is essential to identify which categories of physical exercises (*i.e.* mobilization or stabilization; strengthening or stretching; etc.) should be avoided because they could be detrimental and which should be intensified because they could be useful.

Neuromotor impairments

Many authors have studied the correlation between structural adolescent idiopathic scoliosis and disorders of the vestibular system.^{4, 13, 24, 30-38} Dubousset³⁰ asserts that idiopathic scoliosis is caused by a change in the centers of proprioception and that the deformation is a natural response to the need to restore postural equilibrium. Herman³¹ showed that idiopathic scoliosis is the result of a new neuromotor strategy, adopted as an adjustment to disorders in central (oculomotor) and axial motor control systems (Fig. 2).

Nachemson and Sahlstrand,³² reviewing all theories on the etiology of adolescent idiopathic scoliosis, maintain that the deformity is the result of a delayed maturation of some movement and posture centers and that it is possible, when the stability of the spine is good, to obtain a neutralization of postural deficit in initial scoliosis and, consequently, a stationary or regressive curve.

All these hypotheses relate to different points of the whole system that controls posture and movement. Irrespective of the point actually involved, it is reasonable to assume that training this system could be useful.

It thus emerges, from all this information, that physical activities have an important role to play. This role can be summarized in two therapeutic aims:

- development of spinal stability;
- development of balance.

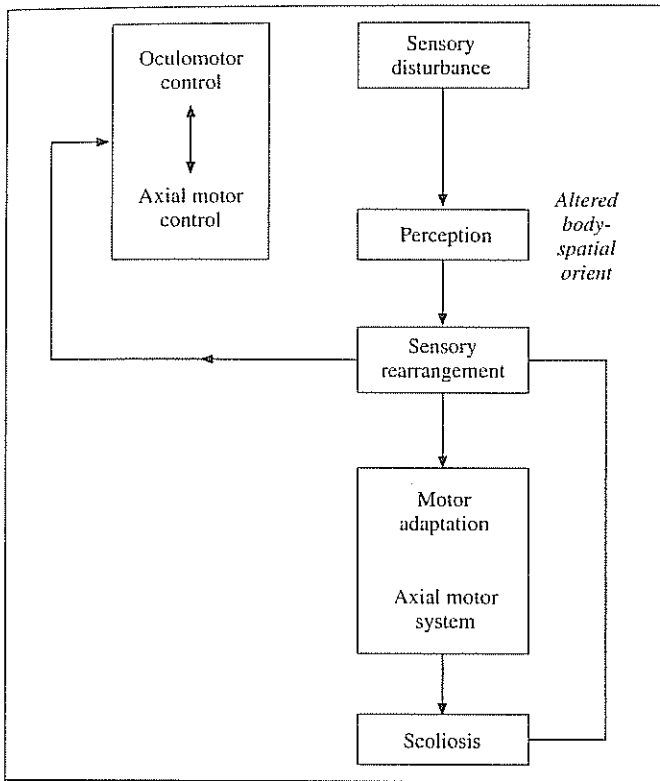


Fig. 2.—According to Herman²² it is possible to propose a cortical model for scoliosis: "Altered body-spatial (visual) orientation leads to sensory rearrangement, an adaptive process to restore perceptual dysfunction; sensory rearrangement is associated with reinterpretation and, hence, recalibration of somatosensory signals conveying information of an erect spine. Motor adaptation of the axial motor system ensues when the subject maintains modified perceptual analysis of proprioceptive information describing an erect spine. A new motor control strategy is adopted resulting in the structural deformity of idiopathic scoliosis. Rearrangement also may have a profound effect on brain stem functioning, thus modifying the oculomotor and axial-motor control systems".²²

As Stagnara¹³ asserts, if we accept that one of the causes of scoliosis is a disorder of the equilibrium systems, it is logical to orientate physical exercise therapy in this direction.

These goals can, through different modes of action, be achieved with physical activities:

- sportive activities produce an increase in general coordination, spinal proprioception and movement control; obviously, in this respect some activities are presumably better than others;

- kinesitherapy, using specific exercises specially developed with these aims in mind, involves a more precise and localized action on the spine, focusing

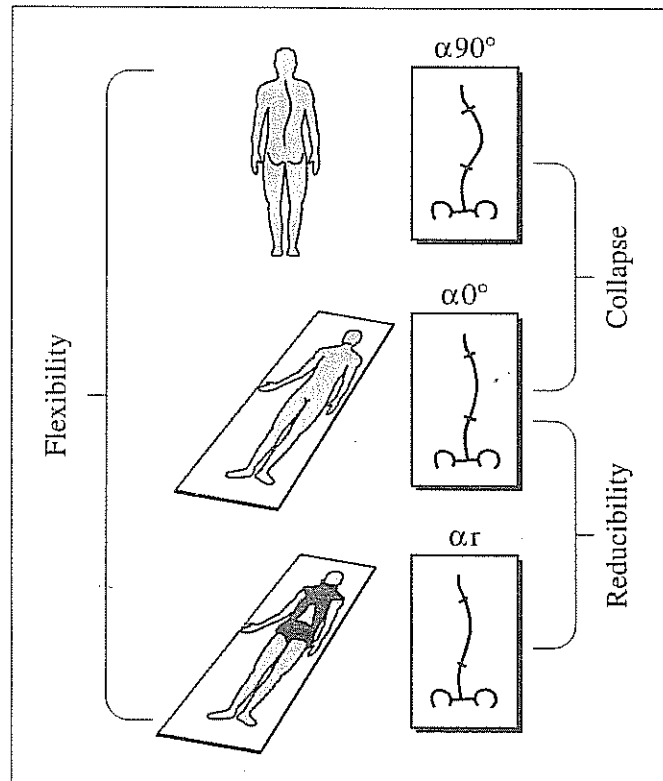


Fig. 3.—When evaluating radiographically a patient with idiopathic scoliosis, it is possible to find different values of Cobb angles in different positions. Duval-Beaupère⁴¹ considered the differences between standing, supine and maximal correction (as achieved with a cast) and defined the values obtained as follows: standing - correction = "flexibility"; standing - supine = "postural collapse"; supine - correction = "reducibility". For example, in a typical patient it is possible to obtain 40° in standing position, 30° in supine position and 18° in correction: flexibility is 40°-18°=22°; postural collapse is 40°-30°=10° and reducibility is 30°-18°=12°.

on the ability of this structure to control itself in space.

Each of these interventions can presumably increase the efficacy of the other, and neither of the two should be undervalued.^{39, 40}

Postural collapse and stabilization

The concept of postural collapse has been defined by Duval-Beaupère.⁴¹ According to this author it is necessary, when evaluating the flexibility of a scoliotic curve, to distinguish between the reducibility index (the difference between a radiographic examination of the same patient in supine position and

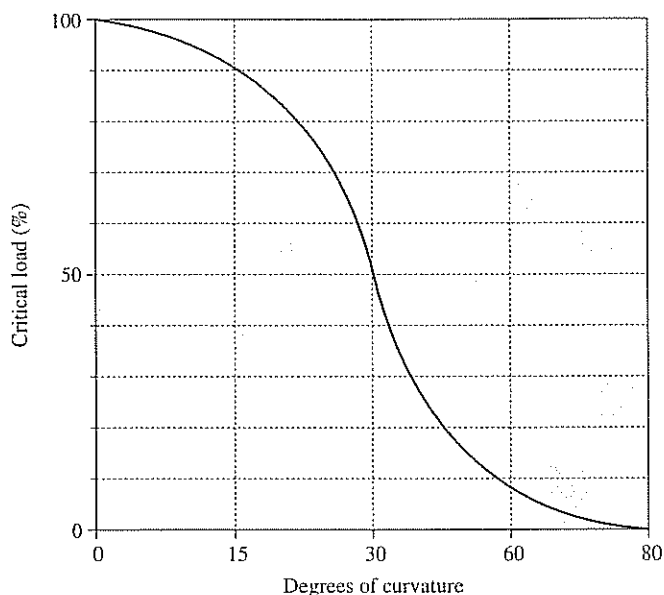


Fig. 4.—The critical load (*i.e.* the threshold beyond which deformation of the spine begins) of the scoliotic spine varies according to the degree of scoliotic curvature,⁴³ independently of the component (postural or structural) to which the curve is due. This graph shows that the higher the Cobb value of the curve, the more easily the scoliotic spine will be aggravated.

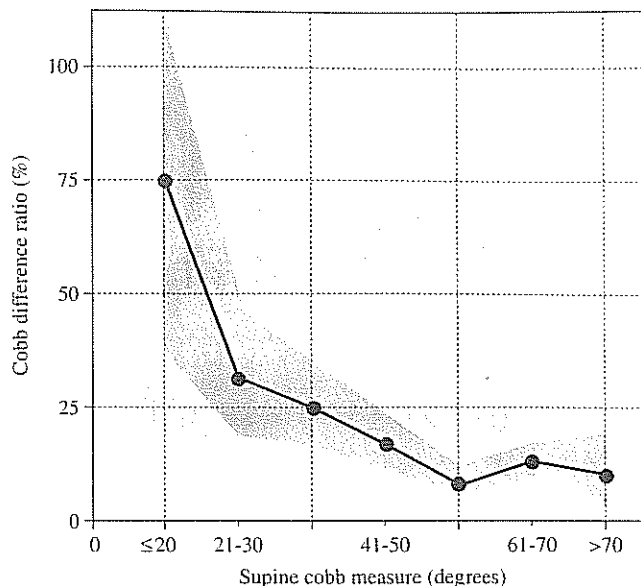


Fig. 5.—According to Torrel and Nachemson⁶⁰ the postural component is higher in curves in which the structural component is less prevalent. In this graph, the postural component is expressed as the "Cobb difference ratio", obtained from the Cobb values of standing and supine radiographs with the formula (standing - supine)/supine; the structural component (*i.e.* the curve severity) is expressed as the supine Cobb measure; the shaded area represents one standard deviation. According to these data, on average in a 20° supine curve the Cobb difference ratio is 75% (*i.e.* the standing measure is 35°) while in a 70° supine curve it is 10% (*i.e.* the standing measure is 77°).

in maximal correction), which is related to the extensibility of the tissues on the concave side, and postural collapse (the difference between a radiographic examination of the same patient in standing and supine position) which correlates only with the ability of the postural system to counteract the force of gravity. According to Duval-Beaupère postural collapse is due to the muscular tone and the extensibility of the tissues on the convex side of the scoliotic curve (Fig. 3). Postural collapse could be reduced by means of physical exercises specifically studied to improve muscular tone and to produce a stabilizing effect.

Patwardan⁴² studied the critical load threshold beyond which deformation of the spine begins and demonstrated that a greater angle of the curve in a standing position corresponds to a lower deformation threshold (Fig. 4), *i.e.* to an increase of the risk of progression. There is, therefore, a clear biomechanical advantage to be obtained by decreasing the postural collapse percentage, which according to Torrel and Nachemson⁴³ is, indeed, particularly high in mild scoliosis (below 20°), (Fig. 5).

Finally, in this respect Panjabi and Abumi⁴⁴ main-

tain that the scoliotic spine, being more unstable than the normal one, needs greater active muscular support in order to maintain the axial posture.

On the basis of these considerations it follows that physical exercises could be useful if they are aimed at developing postural control as formerly described. In any case, it is important to stress the need, in correct posture, to strengthen the muscles of the spine mainly in their antigravitational function (*i.e.* by means of isometric and eccentric contractions and not isotonic, dynamic or isokinetic ones). It is not, in fact, possible to achieve postural control and stabilization without good muscular effectors able to maintain the correct posture for a sufficient length of time.

This is obviously a typical domain of kinesitherapy, in which the specific training of certain muscles is possible using certain kind of contraction. Sport, in this case, is useful only so far as it helps the patient to become better acquainted with his neurological and muscular-skeletal structures, effectors of the intervention.

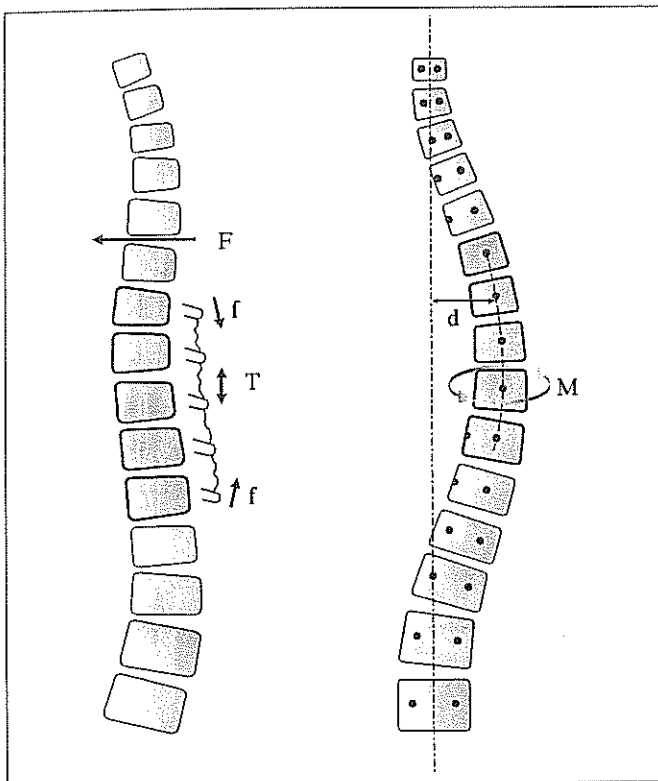


Fig. 6.—Hypothesis of the instability in the rotator plane of a spine in which a sagittal curve reduction (on the left) is combined with a lateral deviation (on the right) according to Dickson.¹² The biomechanical formula is: $M \propto F \cdot d$, where M = spinning moment; f = reactive force; d = distance of coronal plane asymmetry from midline. In the figure: F = force of forward flexion; T = tightening of posterior structures. According to this assumption, the presence of a lateral curvature of the spine with a reduction of the sagittal curves increase the probability of appearance of a rotation of the vertebra causing a structural deformity.

Biomechanical impairments: three-dimensional mechanics of the spine

While it is only recently that the presence of neuromotor impairments in idiopathic scoliosis patients has been highlighted by research, the presence of biomechanical damages has long been documented and is already well understood. However, new data on biomechanical impairments have recently come to the fore and precious information about physical exercise in the three planes of space has emerged from a growing understanding of the three-dimensional mechanics of the scoliotic spine.^{22, 45-53} We will present these data according to a classification based on geometrical body planes:

— horizontal: in this plane the normal spine presents no curves, while the scoliotic spine develops one of its characteristic deformities, vertebral rotation, which provoke the hump;

— sagittal: in this plane the normal spine presents kyphosis and lordosis; in the past these features were not thought to be related the scoliotic curve;

— frontal: in this plane the normal spine presents no curves, while the scoliotic spine develops its characteristic curves.

Horizontal plane

Stagnara¹³ points out that beyond a certain degree of rotation, muscular forces exert an autodeforming action. He also cites the study carried out by Dimnet, who calculated the rotation limit of the apical vertebra to be 20° (the limit beyond which the actions of the spinal muscles of the concave and convex side become agonist).

Geyer⁴⁸ and Vercauteren⁴⁹ conducted research into the autodeforming action of the scoliotic thorax. Vercauteren calculated that once the scoliosis reaches the threshold of 10 mm of the thoracic hump, the subsequent deformation of the thoracic cylinder is sustained by an autodeforming action.

This is why physical exercise (both sport and kinesiotherapy) may be damaging when applied as the sole therapy in scolioses which exceed the autoincreasing threshold. It should also be noted that increased pressure values inside (respiration) or outside (water) enhance the autodeforming mechanism: in fact Geyer⁴⁸ stated that, from a biomechanical point of view, swimming serves no purpose for scoliotic patients. Moreover, it is known that in scoliotic patients swimming does not help to increase neuromotor control.⁵⁰

Sagittal plane

Perdriolle²² showed that in cases of thoracic and thoracolumbar scoliosis the deformity in the sagittal plane manifests itself especially in the initial phases of evolution of the scoliosis with a progressive movement toward hypokyphosis. Graf⁵¹ maintains that, during the evolution of lumbar scoliosis, the line of the gravity centers of vertebral bodies projects itself first sideways and then backwards, thus producing a kyphotizing action on the lumbar spine. According to these two authors, scoliosis seems, in the sagittal

plane, to present as a deformity that reverses the physiological curves of the spine.⁹

According to Dickson⁵² a reduction in the sagittal curves, combined with a lateral deviation, leads to a mechanism of instability in the rotator plane which favors the onset and increase of scoliosis (Fig. 6). White and Panjabi,⁵³ meanwhile, studied the structure of zygapophyses, showing that their anatomical orientation facilitates axial vertebral rotation in conditions of dorsal hypokyphosis and lumbar delordosis.

These data suggest the importance of postures and movements studied in order to maintain or to recover the physiological curves in the sagittal plane with the aim of checking rotator instability.⁷ Also these elements, are relevant to kinesitherapeutic intervention, which should avoid a complete reliance on the classical movement^{13,14} of "auto-elongation" (*i.e.* a simple action of lengthening of the spine on a sagittal axis, that certainly reduces the scoliotic lateral-flexion, but also increases the pathological decrease of kyphosis and lordosis): for each patient a new, three dimensional movement named "auto-correction",^{7,9} composed of de-rotation, de-flexion and maintenance of sagittal curves (slight thoracic kyphotization and lumbar lordosization) should be established on the basis of his particular curve. Also the eventual choice of sporting activities should be guided by considerations of this type: for example, many types of repetitive movements present in agonistic gymnastics, or some kinds of dance could be detrimental.

Frontal plane and mobility of the spine

Perdriolle²² demonstrated that in the frontal plane the range of movement of the scoliotic curve is greater in the direction of the correction than in the direction of progression (Fig. 7); he also asserted that this mobility increases, particularly on apical segments, as the scoliosis evolves. Stagnara¹² was thus right to warn therapists not to mobilize a scoliotic curve without ensuring that the reduction of the same is maintained by means of a passive or active support. On the other hand, the deviation increases during the time in which the spine is not submitted to corrective action.

As with mild scoliosis, the supporting action is developed only through neuromuscular forces: this means, therefore, that increased spinal flexibility must

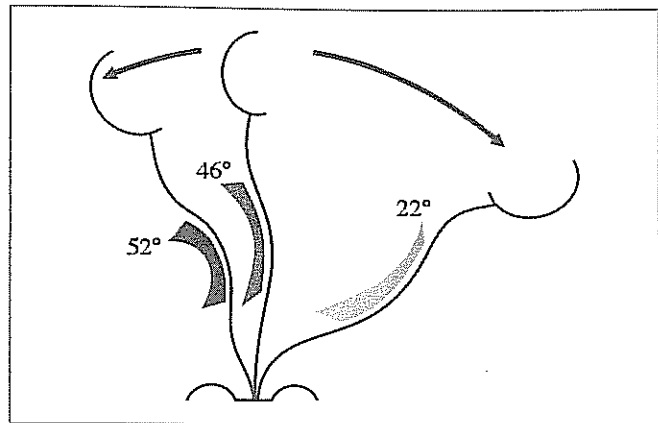


Fig. 7.—According to Perdriolle,⁴⁴ in the frontal plane the range of movement of the scoliotic curve is superior in the direction of the correction than in the direction of progression.

be considered a contraindication and, as underlined above, a stabilization of the spine possibly obtained through the strengthening of the antigravitational muscles, an important objective. In this respect, sporting activities should be approached with caution, while during kinesitherapy physical exercises that increase spinal mobility should be avoided.^{12, 22}

Organic and psychological impairments and disabilities

A scoliotic patient is more than just a spine and a complete approach to the growing adolescent is absolutely essential.

Data obtained from research show that some organic functional deficits, such as the decrease of vital and effort capacity, gradually increase while scoliosis is still in a mid stage of gravity. Milner⁵⁵ reports the presence of a deficit of vital capacity in one patient in three affected by 20° to 40° scolioses. Research conducted in the USA by Di Rocco⁵⁶ produced an analogous maximum VO₂ result in a group of adolescents with scolioses ranging from 25° to 45°.

Another study by Fallstrom, Cochran and Natchemson⁵⁷ showed that scoliosis leads to the development of a negative body image in adolescent subjects, just as they are going through a delicate stage in the formation of their own identity, a factor which may jeopardize the development of a mature and balanced personality in adulthood.

This is why we believe it is so important, for preventive reasons, to encourage patients affected by mild scoliosis to take part in sporting-recreational activities that lead to both psychophysical and basic motor achievements.⁵⁸⁻⁶² Even though for biomechanical and neuromotorial reasons, it may sometimes be useful to suggest one sporting activity rather than another, we think that an excessive "medicalization" — *i.e.* imposition by physicians and/or parents of the type of sport to be practiced by the patient, that preclude his free choice in the matter — should be avoided when possible, mainly for the important psychological reasons we have just mentioned.

Conclusions

Cobb asserted that physical exercise is beneficial when practiced in order to improve the muscle strength and tone, vital capacity and posture of the scoliotic subject.⁶³ Knowledge emerging from scientific research data, according to the review of the literature proposed in this paper, confirms the validity of these assertions.

In adolescent idiopathic scolioses in a phase of development or those which exceed a given risk threshold, there is an undoubted need for appropriate orthopedic and/or surgical therapies in order to stop the evolution and correct the spinal deformities. Nevertheless, in the initial phase of the disease, when the risk of evolution is reduced⁶⁴ and the critical load threshold⁴² and the postural collapse percentage⁴³ are high, physical exercise:

- prevents or reduces disabilities of the scoliotic patients;^{7, 8, 28, 39, 56, 55, 61, 63}

- facilitates the neutralization of postural deficits to produce, as a consequence, a stationary or regressive curve.^{5, 6, 15, 17, 65, 66}

More studies are needed to confirm or reject these conclusions which, derived from an analytical review of the literature, appear reasonable. However, until new results are available, we should not prevent our scoliotic patients from taking part in sporting activities, particularly at school. On the contrary, with the exception of sports that increase mobility, (and even then, only when progression is possible), such activities should be encouraged. The use of appropriate kinesitherapy to increase postural stability is theoretically correct, although a more accurate and detailed risk/benefits analysis is needed.

Riassunto

Ruolo della cinesiterapia nel trattamento della scoliosi idiopatica adolescenziale minore. Revisione della Letteratura.

La cinesiterapia è un programma di esercizi fisici specificamente sviluppato da un fisioterapista ben allenato allo scopo di prevenire o frenare l'aggravamento della deformità nelle scoliosi minori, e prevenire i danni del corsetto, accentuandone gli effetti correttivi, nelle scoliosi di media gravità. In questo studio analizziamo i dati della ricerca per verificare quali, tra le disfunzioni e le alterazioni provocate dalla scoliosi, possono essere prevenute o ridotte da una adeguata cinesiterapia e, di conseguenza, quali sono gli obiettivi terapeutici da perseguire con l'esercizio fisico.

Numerosi Autori hanno studiato le correlazioni fra scoliosi idiopatica e disfunzioni del sistema neuromotorio. Da un'attenta analisi degli studi di Dubousset, Herman, Nachemson e Stagnara derivano i seguenti obiettivi da perseguire nel paziente scoliotico: lo sviluppo della stabilità vertebrale e lo sviluppo delle reazioni di equilibrio. Dagli studi sul collasso posturale, condotti in particolare da Duval-Beaupère e Patwardan, risulta evidente il vantaggio per il paziente scoliotico di un miglior controllo posturale del rachide conseguito tramite il rafforzamento dei muscoli antigravitari del tronco, con esercizi eseguiti in postura corretta e in varie situazioni statiche e dinamiche.

Dalle conoscenze della biomeccanica tridimensionale del rachide scoliotico si evidenziano altre preziose indicazioni sull'influenza dell'esercizio fisico sui tre piani dello spazio. Stagnara afferma che, sul piano trasversale, oltre un certo grado di rotazione della vertebra apicale, le forze muscolari agiscono in senso autodeformante. Pertanto la cinesiterapia può essere benefica solo nelle scoliosi minori, in quanto non superano ancora tale soglia; in caso contrario è pericoloso illudersi di arrestare l'aggravamento con la sola rieducazione. Perdiolle ha dimostrato che nelle scoliosi dorsali e dorsolombari la deformità sul piano sagittale evolve in estensione, soprattutto nelle fasi iniziali dell'aggravamento, mentre Graf afferma che nell'evoluzione delle scoliosi lombari la linea dei centri di gravità dei corpi vertebrali si proietta prima lateralmente e poi posteriormente, determinando così un'azione cifottizzante del rachide lombare. Queste conoscenze ci devono indurre all'uso di posture ed esercizi che mantengano o recuperino le curve fisiologiche sul piano sagittale. Sul piano frontale Perdiolle ha dimostrato che l'ampiezza di movimento della curva scoliotica nel senso della correzione è di gran lunga superiore al senso dell'aggravamento, e che tale mobilità aumenta con l'evoluzione della scoliosi. A sua volta Stagnara ammonisce i terapisti a non mobilizzare una curva scoliotica senza assicurare nel tempo il mantenimento della riduzione con un mezzo di sostegno; in caso contrario la deviazione è destinata ad aggravarsi. Senza la protezione di un'ortesi pertanto, sono controindicati gli esercizi e le attività motorie che aumentano la flessibilità del rachide scoliotico. In particolare tutte quelle tecniche «cosiddette correttive» che impiegano esercizi mobilizzanti asimmetrici o in estensione del rachide, come pure le attività motorie, non praticate in forma ricreativa, che sviluppano notevolmente la mobilità vertebrale (ad esempio: il nuoto, la ginnastica artistica e ritmica, la danza, ecc.).

Millner e Di Rocco hanno rilevato che alcuni deficit funzionali, come la riduzione della capacità vitale e della capacità di sforzo, iniziano quando le scoliosi sono ancora di media gravità. In campo psicologico Fallstrom, Cochran e Nagemson hanno dimostrato che la scoliosi provoca nell'adolescente lo sviluppo di un'immagine negativa del corpo, in coincidenza di un delicato periodo di formazione della sua identità, condizione che potrebbe ostacolare lo sviluppo di una personalità matura ed equilibrata in età adulta. Tali conoscenze evidenziano la necessità di stimolare la partecipazione ad attività motorie globali, anche di tipo sportivo, e di evitare nei giovani scoliotici limitazioni alla vita di relazione.

In conclusione, la deformità scoliotica è il sintomo di una sindrome complessa che coinvolge diverse funzioni dell'organismo a vari livelli, e l'esercizio fisico, se ben indirizzato, può prevenire o ridurre tali disfunzioni nelle scoliosi minori trattate con sola cinesiterapia. Quando la scoliosi è in fase iniziale, il rischio evolutivo è ridotto mentre è notevole il collasso posturale. Di conseguenza, se la cinesiterapia persegue obiettivi terapeutici di stabilità vertebrale, di controllo posturale, di sviluppo delle reazioni di equilibrio e di rafforzamento dei muscoli anti-gravitari in postura corretta, è possibile frenare in molti casi l'evoluzione di una scoliosi minore, come ha dimostrato la ricerca intercentrica, con gruppi di controllo, condotta presso il Centre des Massues di Lione, da Mollon e Rodot (1986) Quando invece una scoliosi evolutiva ha superato una determinata soglia di gravità è assolutamente necessario ricorrere alla terapia ortesica e/o chirurgica.

Parole chiave: Scoliosi idiopatica, terapia - Esercizio fisico - Chinesiterapia.

References

- Bigos S. Acute Low Back Problems in Adults. Clinical Practice Guideline no. 14. AHCPR Publication No. 95-0642. Rockville, MD: Agency for Health Care Policy and Research, Public Health Service, U.S. Department of Health and Human Services, 1994.
- Spitzer WO, LeBlanc FE, Dupuis M. Scientific approach to the assessment and management of activity-related spinal disorders. A monograph for clinicians. Report of the Quebec Task Force on Spinal Disorders. *Spine* 1987;12(7s):1-59.
- Cimino F, Barbieri G, Bertelli G, Nozzi A, Sgarbi C. Kinesiological method in the dry treatment of scoliotic pathologies by the public health service of Modena. In: Proceedings of the 1st International Symposium on 3-D Scoliotic Deformities. Montréal: Gustav Fisher Verlag, 1992:480-7.
- Cristofanilli MA. Nouvelles methodes de kinesitherapie dans la reeducation des scolioses par des techniques basees sur les equilibres. *Resonances Europeennes du Rachis* 1994;3:36-8.
- Mollon G, Rodot JC. Scolioses structurales mineures et kinesitherapie. *Kinesitherapie Scientifique* 1986;244:47-56.
- Ferraro C, Masiero S, Venturin A, Pigatto M, Migliorino N. Effect of exercise therapy on mild idiopathic scoliosis. Preliminary result. *Eur Med Phys* 1998;34:25-31.
- Negrini A, Sibilla P, Negrini S. La cinesiterapia nel trattamento della scoliosi: Nuovi orientamenti metodologici. *Riabilitazione Oggi* 1992;9(4):11-5.
- Negrini S, Negrini A, Sibilla P. La rieducazione del paziente affetto da scoliosi idiopatica. In: *Scoliosis: State of the Art*. Barcellona: Société Internationale de Recherche et d'Etude sur le Rachis, 1996:68-71.
- Negrini S, Sella U. La riabilitazione del paziente affetto da scoliosi idiopatica. In: Basaglia N, editor. *Trattato di medicina riabilitativa*. Milano: Idelson-Gnocchi, 2000:1123-47.
- Pirola V. La chinesiterapia nella rieducazione delle scoliosi - I metodi. Milano: Sperling & Kupfer, 1994.
- Pivetta S, Pivetta M. Evolutività e trattamento della scoliosi - 120 storie documentate fino ai trent'anni. Milano: Sperling & Kupfer, 1992.
- Stagnara P. Deviations laterales du rachis: Scolioses structurales. *Enc Med Chir, Appareil Locomoteur*, 15865 G10 Et G20, 1974.
- Stagnara P. Les Deformations du Rachis. Paris: Masson, 1985.
- Stagnara P, Mollon G, Demauroy JC. Reeducation des scolioses. Paris: Exp. Scient. Fran, 1990.
- Weiss HR, Bettany J. The effectiveness of a tree-dimensional exercise regime in the treatment of idiopathic scoliosis. In: *Proceedings of the 1st International Symposium on 3-D Scoliotic Deformities*. Montréal: Gustav Fisher Verlag, 1992:332-9.
- Nagemson AL, Peterson LE. Effectiveness of treatment with a brace in girls who have adolescent idiopathic scoliosis. *Bone Joint Surg* 1995;77A(6):815-21.
- Mooney V, Gulick J, Pozos R. A Preliminary report on the effect of measured strength training in adolescent idiopathic scoliosis. *J Spinal Disord* 2000;13(2):102-7.
- Huang SC. Cut-off point of the scoliometer in school scoliosis screening. *Spine* 1997;22(17):1985-9.
- Koukourakis I, Giaourakis G, Kouvidis G, Kivernitakis E, Blazos J, Koukourakis M. Screening school children for scoliosis on the island of Crete. *J Spinal Disord* 1997;10(6):527-31.
- Soucacos PN, Soucacos PK, Zacharis KC, Beris AE, Xenakis TA. School-screening for scoliosis. A prospective epidemiological study in northwestern and central Greece. *J Bone Joint Surg Am* 1997;79(10):1498-503.
- Bunnel PW. An objective criterion for scoliosis screening. *J Bone Joint Surg Am* 1984; 66:1381-6.
- Perdriolle R. La Scoliose: Son Etude Tridimensionnelle. Paris: Maloine, 1979.
- Duval-Beaupère G, Dubouset J, Queneau P, Grossiord A. Pour une théorie unique de l'évolution des scolioses. *Presse Médicale* 1970;88:1141-6.
- Costanzo G, Frascarelli M. Vestibular lesions and experimental scoliosis. Presented at the 1st European Congress on Scoliosis and Kyphosis. Dubrovnik, Yugoslavia, October, 1983.
- Bienfait M. Scoliosi e terapia manuale. Roma: Editore Marrapese, 1990.
- Souchard Ph E. Méthode Mézières. Paris: Maloine, 1979.
- Stone B, Beekman C, Hall V, Guess V, Brooks HL. The effect of an exercise program on change in curve in adolescents with minimal idiopathic scoliosis: A preliminary study. *Phys Ther* 1979;59:759-63.
- Roach JW. Adolescent idiopathic scoliosis: nonsurgical treatment. In: Weinstein SL, editor. *The Pediatric Spine: Principles and Practice*. New York: Raven Press, 1997:497-510.
- Negrini A. Il Rafforzamento muscolare in soggetti portatori di distorsioni vertebrali. *La Ginnastica Medica* 1987;30:58-60.
- Dubouset J. Etat actuel des hypotheses etiologiques de la scoliose idiopathiques. *Cahiers de Kinesitherapie* 1984;105:11-8.
- Herman R, Mixon J, Fischer A, Maulucci R, Stuyck J. Idiopathic scoliosis and the central nervous system. *Spine* 1985;10:1-14.
- Nagemson A, Sahlstrand T. Etiologic factors in adolescent idiopathic scoliosis. *Spine* 1977;2:176-84.
- Nai Fovino PL, Gremmo M, Ventura F. Lo sviluppo motorio nei distorsioni minori della colonna vertebrale. *Gior Ital Med Riabil* 1989;4(3):294-8.
- Sahlstrand T, Petruson B. A study of labyrinthine function in patients with adolescent idiopathic scoliosis. *Acta Orthop Scand* 1979;50:759-69.
- Sibilla P. Sistema vestibolare e scoliosi: approccio otoneurologico alla valutazione prognostica e diagnostica della scoliosi. Presented at *Pediatria 90*. S. Margherita Ligure: 1990.

36. Sibilla P, Cesarani A, Negrini S, Atanasio S, Alpini D, Romano M *et al.* Stepping coordination in scoliosis evaluated by the mean of cranio-corpography. In: Taguchi K, Igarashi M, Mori S, editors. Vestibular and Neural Front. Amsterdam: Elsevier Science B.V., 1994:39-42.
37. Yamada K, Yamamoto H, Tamura T, Tezuka E. Development of scoliosis under neurological cases, particularly in relation with brain-stem abnormalities. *J Bone Joint Surg* 1974;56A:1764-66.
38. Yamamoto H, Yamada K. Equilibrial approach to scoliotic posture. *Agressologie* 1976;17:61-6.
39. Negrini A, Negrini S. Scoliosi, chinesiterapia e sport. In: Cimino F, editor. *La Scoliosi in Età Evolutiva: Attualità e Tecniche di Trattamento a Confronto*. Modena (Italy): Groupe Kinesitherapique Europeen de Travail sur la Scolios, 1991;21/1-21/4.
40. Negrini S. Sport, zainetto e scoliosi idiopatica: Problemi clinici quotidiani correlati al ruolo del sistema posturale. *La Ginnastica Medica* 1996;39:43-50.
41. Duval-Beaupere G, Lespargot A, Brossiord A. Flexibility of scoliosis: What does it mean? *Spine* 1985;10:428-32.
42. Patwardhan AG, Bunch WH, Meade KP. A biomechanical analog of curve progression and orthotic stabilization in idiopathic scoliosis. *J Biomech* 1986;19:103-17.
43. Torrel G, Nachemson A, Haderspeck K, Shultz A. Standing and supine Cobb measures in girls with idiopathic scoliosis. *Spine* 1985;10:425-7.
44. Panjabi M, Abumi K. Spinal stability and intersegmental muscle forces: a biomechanical model. *Spine* 1989;14:194-200.
45. Duconge P. Progressive puberal scoliosis: Pelvic rotation in horizontal plane: Consequences on curvatures in a sagittal plane. *Resonances Europeennes du Rachis* 1994;3:25-30.
46. Miramand Y. The lumbar spine, pelvis-sacrum, lower limbs complex. *Resonances Europeennes du Rachis* 1994;2:17-8.
47. Perdriolle R, Becchetti S, Vidal J, Lopez P. Mechanical process and growth cartilages: Essential factors in progression of scoliosis. *Spine* 1993;18:343-9.
48. Geyer B. Scoliosè thoracique et sport. Presented at XV Journées du Groupe Kinesitherapique de Travail sur la Scolios. Palavas Les Flots, 1986.
49. Vercauteren M. Trunc asymmetries in a Belgian school population. *Spine* 1982;7:555-62.
50. Negrini S, Corno C. Controllo neuromotorio in acqua nella scoliosi idiopatica adolescenziale. *Eur Med Phys* 1996;32:101-9.
51. Graf H. La derotation de la colonne vertebrale est le principale objectif du traitement. In: *Proceedings of the 1st International Symposium on 3-D Scoliotic Deformities*. Montréal: Gustav Fisher Verlag, 1992:356-8.
52. Dickson RA, Lawton JO, Archer IA, Butt WP. The pathogenesis of idiopathic scoliosis. *J Bone Joint Surg* 1984;66B:8-15.
53. White E, Panjabi A. Kinematics human. *Spine* 1978;3:12-20.
54. Ollier M. A propos de globalite ... "ecoute voir". *Resonances Europeennes du Rachis* 1994;2:20-5.
55. Milner AD, Milner NE. The place of lung function in children with scoliosis. In: *Proceedings of the Zorab Scoliosis Symposium*. London, October, 1983. New York: Praeger, 1985:190-9.
56. Dirocco P, Vaccaro P. Cardiopulmonary functioning in adolescent patients with mild idiopathic scoliosis. *Arch Phys Med Rehabil* 1988;69:198-201.
57. Fallstrom K, Cochran T, Nachemson A. Long-term effects on personality development in patients with adolescent idiopathic scoliosis. *Spine* 1985;10:1-14.
58. Astrand PO. Exercise physiology and its role in disease prevention and in rehabilitation. *Arch Phys Med Rehabil* 1987;68:305-9.
59. Astrand PO, Grimby G. Physical Activity in Health and Disease, *Acta Medica Scandinavica Symposium, Stockholm Series, No. 2*. Stockholm: Almqvist & Wiksell International, 1986.
60. Blomquist CG, Saltin B. Cardiovascular adaptations to physical training. *Ann Rev Physiol* 1983;45:169-89.
61. Caillens F, Jarousse Y, Adrey J, Dimeglio A. Vivre or survivre avec une scoliose de 180 degrees. In: *Echanges En Reeducation*. Montpellier: Sauramps Medical, 1989:317-22.
62. Saltin B, Gollnick Pd. Skeletal muscle adaptability: Significance for metabolism and performance. In: *Handbook of Physiology*. Baltimore: Williams and Wilkins Company, 1983:555-631.
63. Cobb J. Outline for the study of scoliosis. In: *Instructional Course Lectures*. Ann Arbor MI: American Academy of Orthopaedic Surgeons, 1948;5:241-75.
64. Lonstein JE, Carlson M. The prediction of curve progression in untreated idiopathic scoliosis during growth. *J Bone Joint Surg* 1984;66A:1061-71.
65. Klisic P, Nicolis Z. Scoliotic attitudes and idiopathic scoliosis. Presented at the Giornate Internazionali sulla Scoliosi. Roma, 1981.
66. Ottoni MC, Pivetta S. Valutazioni clinico-statistiche sul trattamento incruento della scoliosi. *La Ginnastica Medica* 1987;1-2:23-31.